

Distance vulva-anus=about twice length of tail; eggs $36-41\mu \times 80-100\mu$; stylet $8-10\mu$. ♂ (n 5) total length = .92-1.2 mm; $\alpha=24-31$, $\beta=8.1-10.7$, $\gamma=8.5-14.5$; spicula about 30μ ; gubernaculum $8-10\mu$; stylet $8-10\mu$.

Measurements as given by Bütschli for the type form: ♀ = 1.7 mm; $\alpha=19$, $\beta=10$, $\gamma=13$; $\nu=80\%$; eggs = $50\mu \times 95\mu$; stylet = 13μ . ♂ = 1.4 mm; $\alpha=20$, $\beta=10$, $\gamma=12$.

Emended diagnosis of *A. askenasyi*: Resembling *A. dipsaci* but stouter, vulva more cephalad, bursa shorter, reaching only half, or slightly more than halfway, down the tail; eggs much thicker, deposited unsegmented; intestine of brownish color; female usually assuming shape of a sickle or a more or less rolled-up spiral.

Type host: *Hypnum cupressiforme* Hooker.

Type locality: Feldberg, Taunus (Germany).

In view of the difference in symptoms as caused by Bütschli's type form (ectoparasite, not producing galls) and the present form (entoparasite, producing galls), it is thought best to consider the two as different host varieties, a conception also supported by slight differences in dimensions.

LITERATURE CITED

- BASTIAN, CHARLTON H. *Monograph on the Anguillulidae, or free nematoids, marine, land, and freshwater, with descriptions of 100 new species.* Trans. Linn. Soc. XXV: 73-179, Pls. 9-13. 1865.
- BOS, J. RITZEMA. *L'anguillule de la tige (Tylenchus devastatrix Kühn) et les maladies des plantes dues à ce Nematode.* Arch. Musee Teyler Ser. II, Vol. III, 2^e partie: 161-348, pl. 1-10. 1888.
- BÜTSCHLI, O. *Beiträge zur Kenntniss der freilebenden Nematoden.* Nova Acta Ksl. Leop.—Carol. Deutsch. Akad. Naturforscher 36(5): 1-144, pl. 1-11. 1873.
- HORN-WAREN, PAUL. *Beitrag zur Kenntniss der moos bewohnenden Tylenchus-Arten.* Arch. Ver. der Freunde d. Naturgesch. in Mecklenburg. 63: 67-77. 1909.
- MASSALONGO, C. *Nuovo Elmintocecidio scoperto sulla Zieria julacea Schimp.* Rivista Patologia Vegetale 7(1): 87-89. pl. IV. 1898.
- SCHIFFNER, VICTOR. *Neue Mitteilungen über Nematoden-Gallen.* Hedwigia 45: 159-172. 1906.

ZOOLOGY.—*The histology of nemie esophagi. VII. The esophagus of Leidynema appendiculatum (Leidy, 1850.)*¹ B. G. CHITWOOD, Bureau of Animal Industry, and M. B. CHITWOOD.

This paper is the seventh of a series dealing with the histology of nemie esophagi. In the earlier papers (1934-1936) the esophagi of *Rhabdias eustreptos*, *Oesophagostomum dentatum*, *Heterakis gallinae*, *Metastrongylus elongatus*, *Rhabditis terricola* and *Rhabditis lambdiensis* have been described. The nomenclature used in this paper was explained in the first paper of the series.

GROSS MORPHOLOGY

The length of the esophagus of *Leidynema appendiculatum* usually ranges from 396 to 448 μ in the gravid female, but in the gravid female upon which subsequent measurements are based, it is 364 μ long. It consists of a cylindri-

¹ Received March 13, 1935.

cal precorpus, 126μ long, a subcylindrical postcorpus, 108μ long, a very short narrow isthmus, 36μ long, and a pyriform bulb, 64μ long. The lumen is triradiate; in the corpus and isthmus each radius terminates in an incomplete subcylindrical "tube." The "tubes" are very wide in the precorpus (Fig. 2a), very narrow in the postcorpus (Fig. 2c), and scarcely distinguishable in the isthmus. In the bulb region the sides of the radii converge; in this region the lumen is, of course, modified by the valves. Returning to the lumen of the corpus, we find that in the precorpus the central part of the lumen is open, subtriangular with thickened walls (Fig. 2a-b), while in the postcorpus and isthmus the lumen is closed, not subtriangular and the walls not thickened (Figs. 1b and 2c-d).

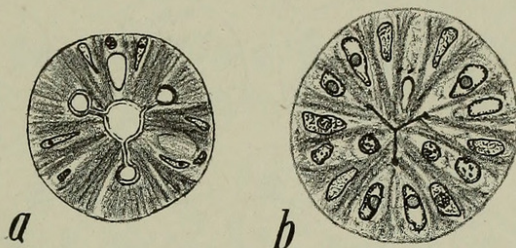


Fig. 1.—Cross section of esophagus. a, Region of precorpus in adult; b, region of postcorpus in adult.

The esophagus of the female fourth-stage larva in the specimen studied is 218μ long and consists of the same parts as in the adult, i.e., precorpus, postcorpus, isthmus and bulb, but the postcorpus is not as wide and the isthmus is very slightly longer. In addition we find that the "tubes" at the ends of the esophageal radii are not as large, the lumen of the precorpus not subtriangular, and its walls not thickened as in the adult.

NUCLEAR DISTRIBUTION

The distribution of nuclei in the esophagus differs slightly in the fourth-stage larva and in the adult. In general, the nuclei are closer together in the larva than in the adult, which is due to the esophagus being shorter; a few of the nuclei differ also in relative position. The nuclei are identical in both stages and for that reason the esophagus of the adult is described, differences in relative position being noted as they occur.

Precorpus.—There are 25 nuclei in the precorpus as follows: 6 radial nuclei (r_{1-6}) and 19 nerve cell nuclei (n_{1-19}). The radial nuclei are situated near the base of the precorpus, and arranged in a single group (r_{1-6}), 1 nucleus on each side of each sector. The nerve cell nuclei are arranged in groups of 3, one in the center of each sector. The first group (n_{1-3}) is situated near the anterior end of the precorpus, the second, third, and fourth groups, (n_{4-6} , n_{7-9} , and n_{10-12}), respectively, follow one another rather closely in series. These are followed by the fifth group (n_{13-15}) which immediately precedes the radial nuclei of the precorpus (r_{1-6}) and the sixth group (n_{16-18}) which is situated

at about the same level as the radial nuclei. The nuclei n_{13} and n_{16} may be identical but in the majority of sections they appear to be separate. In addition to these nuclei there is a single dorsal nerve cell nucleus (n_{19}) situated posterior to n_{17} . In the fourth-stage larva the last 2 subventral nerve cell nuclei are situated at the level of n_{19} instead of at the level of n_{17} . The radial nuclei (r_{1-6}) are situated near the level of n_{10-15} instead of n_{13-18} .

Postcorpus.—There are 22 nuclei in the postcorpus as follows: 3 bilobed marginal nuclei (m_{1-3a} and b), 6 radial nuclei (r_{6-12}), and 13 nerve cell nuclei (n_{20-32}). The radial nuclei (r_{7-12}) are situated anterior to the middle of the postcorpus and arranged in the same manner as those (r_{1-6}) in the

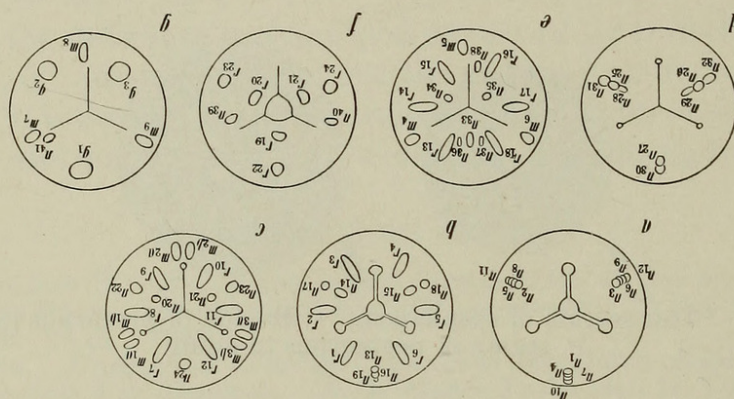


Fig. 2.—Diagrammatic representation of groups of nuclei of esophagus. a-b, Precorpus; c-d, postcorpus; e, prevalvar region; f-g, valvar and postvalvar regions.

precorpus. The marginal nuclei (m_{1-3}) are situated at approximately the same level, 1 lobe of a nucleus being on each side of each esophageal radius (Fig. 1b, m_{1a} and m_{1b}). The nerve cell nuclei (n_{20-32}) are arranged symmetrically in the subventral sector but not in the dorsal sector and for that reason they will be located according to sector. The dorsal sector contains 3 nuclei ($n_{24,27,30}$) the first (n_{24}) being at the level of the radial nuclei (r_{7-12}), the second (n_{27}) some distance posterior to the radial nuclei, and the third (n_{30}) at the base of the postcorpus. Each subventral sector contains 5 nerve cell nuclei ($n_{20-21,22-23,25-26,28-29,31-32}$). The first pair (n_{20-21}) is situated slightly anterior to the level of the radial nuclei, near the lumen of the esophagus, and the second pair (n_{22-23}) is situated at the same level or slightly posterior to the first pair and nearer the external surface of the esophagus. The third subventral pair (n_{25-26}) is situated just anterior to the level of n_{27} ; the fourth pair (n_{28-29}) is situated posterior to the level of n_{27} , being near the external surface of the esophagus; the fifth pair (n_{31-32}) is at approximately the same level as, or slightly posterior to, the fourth group (n_{28-29}). The nerve cells in the fourth-stage larva differ in that n_{20-23} are situated at the level of r_{7-12} , n_{25-26} at the level of n_{27} , and n_{31-32} at the level of n_{30} .

Isthmus.—The isthmus contains no nuclei.

Prevalvar and valvar region.—This region contains 20 nuclei as follows: 9 radial nuclei (r_{13-21}), 3 marginal nuclei (m_{4-6}), and 8 nerve cell nuclei (n_{33-40}). The radial nuclei are arranged in 2 groups, an anterior group of 6 nuclei (r_{13-18}) arranged as are those in the corpus (r_{1-12}), and a posterior group of 3 nuclei (r_{19-21}), 1 near the center of each sector. The nerve cells are arranged as follows: n_{33} in the middle of the dorsal sector just posterior to the level of r_{13} and 18; n_{34} and 35 near the middle of each subventral sector at the same level as n_{33} ; n_{36-37} are situated just posterior to n_{33} , 1 on each side of the

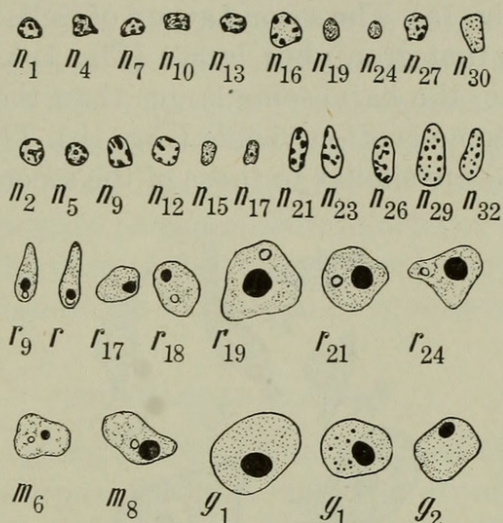


Fig. 3.—Nuclei of esophagus. Marginal, radial, gland nuclei and nuclei of nerve cells.

dorsal sector; n_{38} is situated near the ventral radius in the right subventral sector at approximately the same level as r_{21} ; n_{39-40} are situated posterior to r_{14-17} , respectively, 1 in the lateral part of each subventral sector.

Postvalvar region.—The postvalvar region contains 10 nuclei as follows: 3 radial nuclei (r_{22-24}), 3 marginal nuclei (m_{7-9}), 3 gland nuclei (g_{1-3}), and 1 nerve cell nucleus (n_{41}). The marginal nuclei (m_{7-9}) are situated near the anterior end of the postvalvar region, 1 being posterior to the other 2. One is situated near each esophageal radius, the side at which each nucleus lies being inconstant. The radial nuclei (r_{22-24}) are situated slightly posterior to the marginal nuclei, 1 near the lumen and in the center of each sector. The gland cell nuclei (g_{1-3}) are similarly arranged except that they are posterior to the radials and near the external surface of the esophagus. The single nerve cell nucleus (n_{41}) is situated beside the left subdorsal radius of the esophagus at about the level of the gland cell nuclei.

THE ESOPHAGO-INTESTINAL VALVE

The esophago-intestinal valve consists of an internal trilobed mass of tissue and an external circular layer of tissue. Within the trilobed mass are

2 nuclei, 1 dorsal (e_1) and 1 ventral (e_2). The number of nuclei in the external layer could not be determined with accuracy. Three nuclei, 1 left and 1 right dorsolateral (e_{3-4}) and 1 right or left subventral (e_5), were consistently found. Two additional dorsolateral nuclei (e_{6x-7x}) were found external to e_{3-4} in one specimen. However, it is possible these nuclei might be those of intestinal cells.

CHARACTER OF NUCLEI

The radial nuclei all contain a moderately large karyosome. The nuclei of the precorpus (r_{1-6}) are laterally compressed, and have a clear, lightly basophilic nucleoplasm (Fig. 1a). The second group of radial nuclei are similar in shape to those of the first group but larger (Fig. 1b). The nucleoplasm is slightly less basophilic, the karyosome larger than the karyosomes of r_{1-6} , and a smaller plasmosome is often visible (Fig. 1b). The nuclei of the third group of radials (r_{13-18}) are similar to those of the second group but more or

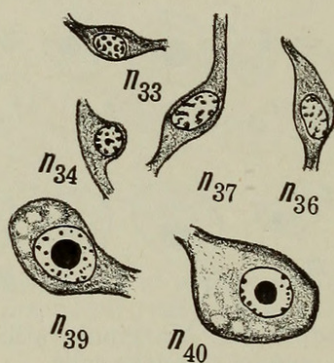


Fig. 4.—Nerve cells.

less ovoid; the nucleoplasm is lightly basophilic, nearly homogenous and each also contains a moderate-sized karyosome and a smaller plasmosome (Fig. 3). The nuclei of the fourth group (r_{19-21}) are rounded in shape, distinctly larger than the others, and each contains a very large karyosome as well as a small plasmosome (Fig. 3). The nuclei of the fifth group (r_{22-24}) are similar to those of the fourth group, but tend to be slightly flattened (Fig. 3).

The marginal nuclei are similar to the radials in general character but the nucleoplasm appears to be more reticular (Fig. 3). Each of the marginal nuclei of the postcorpus (n_{1-3}) consists of a posteriorly bilobed body which in cross section appears as 2 nuclei (Fig. 3), each containing a moderate-sized karyosome and a small plasmosome. The marginal nuclei (m_{4-6}) are not lobed but tend to be irregular in shape due to pressure from the marginal fibers; each contains a large karyosome and a small plasmosome (Fig. 3a). The marginal nuclei (m_{7-9}) are ovoid and similar to m_{4-6} .

The nuclei of the esophageal glands (g_{1-3}) are similar in general character to those of the radial nuclei r_{19-24} in having a large karyosome, small plasmosome, and delicately basophilic nucleoplasm (Fig. 3a); in some specimens

small clumps of granules occur in the nucleoplasm. The dorsal gland nucleus (g_1) is the largest nucleus of the esophagus, the subventrals (g_{2-3}) being but slightly smaller.

The nuclei of the nerve cells (n_{1-41}) differ from all other nuclei of the esophagus and are similar to one another in that the nucleoplasm contains large basophilic clumps (Fig. 3a) which make them much darker than other nuclei; in general neither karyosome or plasmosome may be observed. The nerve cell nuclei fall into 3 general groups as follows: Small nuclei ($n_{1-19,24,27}$), about 1.15 to 3.3μ long by 1.2 to 2.9μ wide in cross section, with rather coarse basophilic deeply staining material; medium-sized nuclei ($n_{23,25-26,28-38,41}$), about 3 to 5.9μ long by 1.87 to 2.6μ wide in cross section, with fewer basophilic clumps in proportion to the size of the nucleus; large nuclei (n_{39-40}), about 5 to 5.9μ long by 4.3 to 4.5μ wide in cross section. The nuclei of the first type belong to bipolar neurones of the 3 anterior esophageal nerves. The cell bodies of these neurones are extremely narrow. The neurones of the second and third types appear to be commissural nuclei of the postcorpus and bulbar regions. These neurones of the second type have moderate-sized cell bodies (Fig. 3b) and those of the third type have massive cell bodies (Fig. 3b).

ESOPHAGEAL GLANDS

The dorsal esophageal gland opens into the lumen of the esophagus at the anterior end of the precorpus. Its duct and finer structure are similar to those of the dorsal esophageal gland of *Rhabditis* (see Chitwood and Chitwood, 1936). It is difficult to trace the glandular protoplasm in the bulb and particularly to distinguish between it and the sarcoplasm of muscle cells. The large nucleus (g_1) apparently lies within the gland tissue, but it may not; we have attributed the nucleus r_{19} to radial muscle, although there is the possibility that it should be attributed to the dorsal gland, and g_1 to the radial muscle; further study is necessary to determine this point with certainty.

The subventral esophageal glands open into the lumen at the posterior end of the postcorpus near the level of n_{30} . They also are similar to the esophageal glands of *Rhabditis* except that they are situated near the middle of the subventral sectors in the bulbar region and not in the lateral part of these sectors. The same difficulties were encountered regarding the nuclei of the glands as were encountered in the case of the dorsal gland. It is possible that the nuclei r_{20-21} should be attributed to the glands and that g_{2-3} should be attributed to the radial muscles. However, the interpretation which the writers have given to these nuclei seems to be correct.

LITERATURE CITED

- CHITWOOD, B. G., and CHITWOOD, M. B. *The histology of nemic esophagi*. Parts I, II. Z. Zellforsch. u. mikrosop. Anat. **22**: 29-37, 38-46. 1934. Part III. This JOURNAL, **24**: 557-562. 1934. Part IV. Ibid. **25**: 230-237. 1935. Part V. Ibid. **26**: 52-59. 1936. Part VI. Ibid. **26**: 331-346. 1936.



Chitwood, B. G. 1936. "The histology of nemic esophagi. VII. The esophagus of *Leidynema appendiculatum* (Leidy 1850)." *Journal of the Washington Academy of Sciences* 26, 414–419.

View This Item Online: <https://www.biodiversitylibrary.org/item/123166>

Permalink: <https://www.biodiversitylibrary.org/partpdf/101416>

Holding Institution

Smithsonian Libraries and Archives

Sponsored by

Biodiversity Heritage Library

Copyright & Reuse

Copyright Status: Permission to digitize granted by the rights holder

Rights: <https://www.biodiversitylibrary.org/permissions/>

This document was created from content at the **Biodiversity Heritage Library**, the world's largest open access digital library for biodiversity literature and archives. Visit BHL at <https://www.biodiversitylibrary.org>.