

22.

Lymphocystis in the Hogfish, *Lachnolaimus maximus*.

R. WEISSENBERG

Department of Cytology
Washington University Medical School

R. F. NIGRELLI

New York Aquarium

G. M. SMITH

Department of Anatomy
Yale School of Medicine

(Text-figure 1).

One of several hogfish (*Lachnolaimus maximus*) received at the New York Aquarium in July, 1937, developed soon after arrival a number of small cutaneous tumors. With the use of a magnifying lens these tumors suggested lymphocystis disease, because they consisted of groups of small grayish-white colored nodules. These were distributed along the sides of the body, and on the dorsal, pectoral and tail fins.

The microscopic study of an excised piece from the border of a fin showed, both in total preparations and in the paraffin sections, that these lesions were clearly lymphocystis disease.

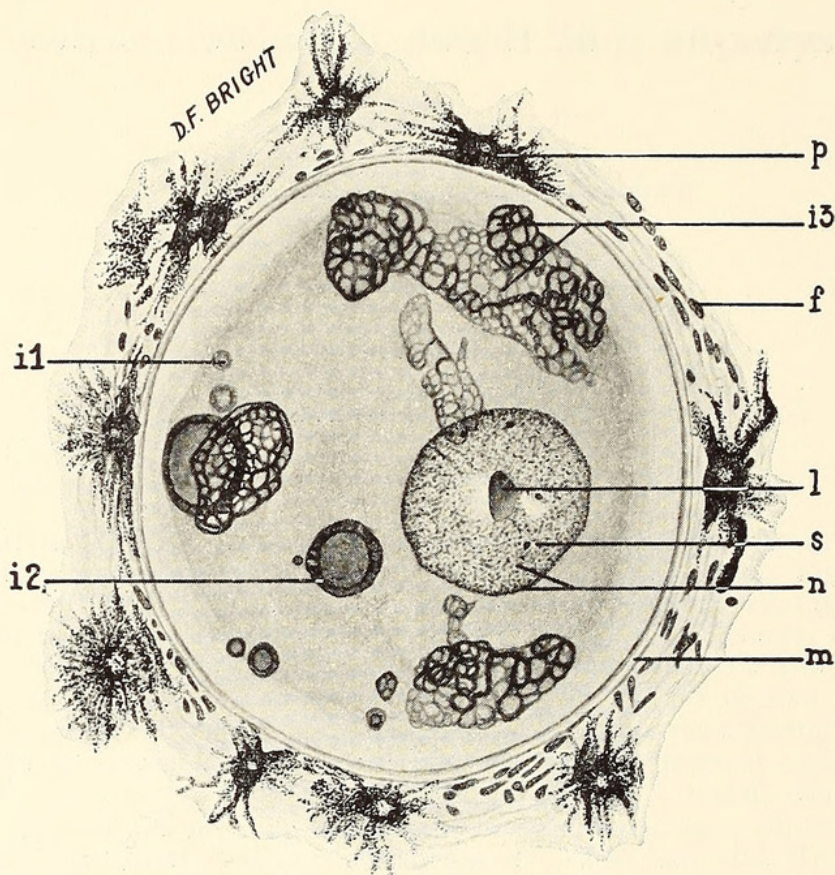
It is in the connective tissue of the fin host that the characteristic large lymphocystis cells were seen. These cells are similar to those noted by Weissenberg (1914, 1920, 1922) in two European species of fishes, the flounder (*Pleuronectes flesus*) and the ruffe (*Acerina cernua*), and more recently in America by Smith and Nigrelli (1937) in the angelfish (*Angelichthys isabelita*).

The lymphocystis cells have several conspicuous points of distinction. The cells, possessing only one nucleus, reach gigantic size; they are surrounded by a thick hyaline cell membrane; and finally, the cytoplasm contains very striking inclusion bodies which consist of a delicate network staining like the basophilic chromatin of the nucleus.

Text-figure 1 shows these characteristics in a relatively young lymphocystis cell, sketched from a total preparation stained with Delafield's hematoxylin. This oval-shaped cell measured 120 x 100 microns. It is surrounded by small connective tissue cells (f) and pigment cells (p). The enlarged nucleus (n) contains fine chromatin granules, one large nucleolus (l) and several smaller nucleoli (s). The cytoplasm, surrounded by the thick membrane, contains thirteen inclusion bodies of various sizes and form. These were sketched from different optical levels in relation to the nucleus. The dark bodies (i 2) lie in a plane above the nucleus, the

light gray (i 1) below the nucleus. Cell inclusions showing reticulated formation were chiefly demonstrable at about the level of the nucleus (i 3).

Because of the fact that there are numerous inclusion bodies, the lymphocystis cells in the hogfish more closely resemble those of the flounder. However, the reticulated bodies of the hogfish differ from those of the flounder lymphocystis cells of similar size in that they are of a more compact form. In the lymphocystis cells of *Acerina*, on the other hand, only one network of inclusion bodies surrounds the nucleus.



Text-figure 1.

Total preparation of lymphocystis nodule of hogfish, *Lachnolaimus maximus*. Stained with Delafield's hematoxylin. x 600. See text for explanation.

The smallest lymphocystis cells found in the tumors of the hogfish have a diameter of 120 microns, while the largest reach a size of 530 microns. The increase in size of the lymphocystis cells is usually accompanied by an increase in the number of inclusion bodies.

As to the interpretation of lymphocystis cells, Weissenberg (1914) has shown that they are not protozoa, but hypertrophied connective tissue cells of the host, probably stimulated to gigantic growth by the action of an intra-cellular virus.

It is interesting to point out here that the two species of fishes (*Angelichthys isabelita* and *Lachnolaimus maximus*) in which this disease has been recently found were collected at Key West, Florida.

REFERENCES.

WEISSENBERG, R.:

1914. Über infektiöse Zellhypertrophie bei Fischen (Lymphocystiserkrankung). *Sitzungsberichte der Königlich Preussischen Akademie der Wissenschaften*. 30: 792.
1920. Lymphocystisstudien. (Infektiöse Hypertrophie von Stützgewebszellen bei Fischen). *Archiv f. Mikroskopische Anatomie*. 94: 55.
1921. Lymphocystiskrankheit der Fische. *Handbuch der Pathogenen Protozoen* von v. Prowazek-Nöller. 3: 1344.

SMITH, G. M., & NIGRELLI, R. F.:

1937. Lymphocystis Disease in *Angelichthys*. *Zoologica*. 22: 293.



Weissenberg, Richard, Nigrelli, Ross F., and Smith, G M . 1937. "Lymphocystis in the Hogfish, *Lachnolaimus maximus*." *Zoologica : scientific contributions of the New York Zoological Society* 22(22), 303–305.

<https://doi.org/10.5962/p.203687>.

View This Item Online: <https://www.biodiversitylibrary.org/item/207462>

DOI: <https://doi.org/10.5962/p.203687>

Permalink: <https://www.biodiversitylibrary.org/partpdf/203687>

Holding Institution

Smithsonian Libraries and Archives

Sponsored by

Biodiversity Heritage Library

Copyright & Reuse

Copyright Status: In Copyright. Digitized with the permission of the rights holder

Rights Holder: Wildlife Conservation Society

License: <http://creativecommons.org/licenses/by-nc/3.0/>

Rights: <https://www.biodiversitylibrary.org/permissions/>

This document was created from content at the **Biodiversity Heritage Library**, the world's largest open access digital library for biodiversity literature and archives. Visit BHL at <https://www.biodiversitylibrary.org>.