

1
2910

Car. Hist.

THE LIBRARY OF THE

APR 13 1944

UNIVERSITY OF ILLINOIS

ZOOLOGICAL SERIES

OF

FIELD MUSEUM OF NATURAL HISTORY

Volume 29

CHICAGO, MARCH 28, 1944

No. 10

MASTICATORY APPARATUS OF THE SLOTHS

BY HARRY SICHER

FOUNDATION FOR DENTAL RESEARCH, CHICAGO COLLEGE OF DENTAL SURGERY

A descending processus of the zygomatic arch has been developed independently in widely separated orders of mammals. It is characteristic of the living Bradypodidae and of many extinct edentates (Glyptodontidae and Gravigrada). It is found in *Diprotodon* and indicated in the Macropodidae. In the Entelodontidae it reached its highest development. Although several explanations have been advanced for its functional significance in the entelodonts no attempt has been made to correlate its presence in the Bradypodidae to a specific functional adaptation of the masticatory apparatus. The present investigations disclose the curious fact that the mechanism of mastication in the two-toed sloth is, in a sense, of an opposite type from that in the three-toed sloth.

The present study is based on the skeletal material of Field Museum of Natural History and the dissection of one specimen of *Bradypus* and one specimen of *Choloepus* from the United States National Museum. I wish to express my appreciation to these institutions for their generosity. The drawings are the work of Miss Peggy Collings.

REVIEW OF LITERATURE

Schulman (1906) gave a fairly accurate description of the masseter muscle in *Choloepus*. He states that "the masseter muscle of Ch. Hoffmani arises from both surfaces of the zygomatic arch, which is partly represented by a ligament, and mostly from the zygomatic bone; it does not split completely into an outer and inner layer according to its outer and inner origin. On the contrary, the masseter remains united immediately below the zygomatic arch." . . . "The main direction of the fibers is from anterior and superior to posterior and inferior." . . . "The masseter is a multipennate

muscle, the entire mass of which converges toward the angulus mandibulae." . . . "The strong tendency of the fibers to assume a position in the sagittal plane leads to a combined pressure of the mandible anteriorly and superiorly against the maxilla."

Lubosch (1908) investigated the temporo-mandibular articulation in *Choloepus* and *Bradypus*. A disk is lacking in both genera. In correct occlusion of the teeth in *Bradypus* the condyle occupies only the most ventral part of the wide articular fossa.

Statements as to the presence or absence of a sterno-mandibular (sterno-maxillary) muscle vary considerably. According to Windle

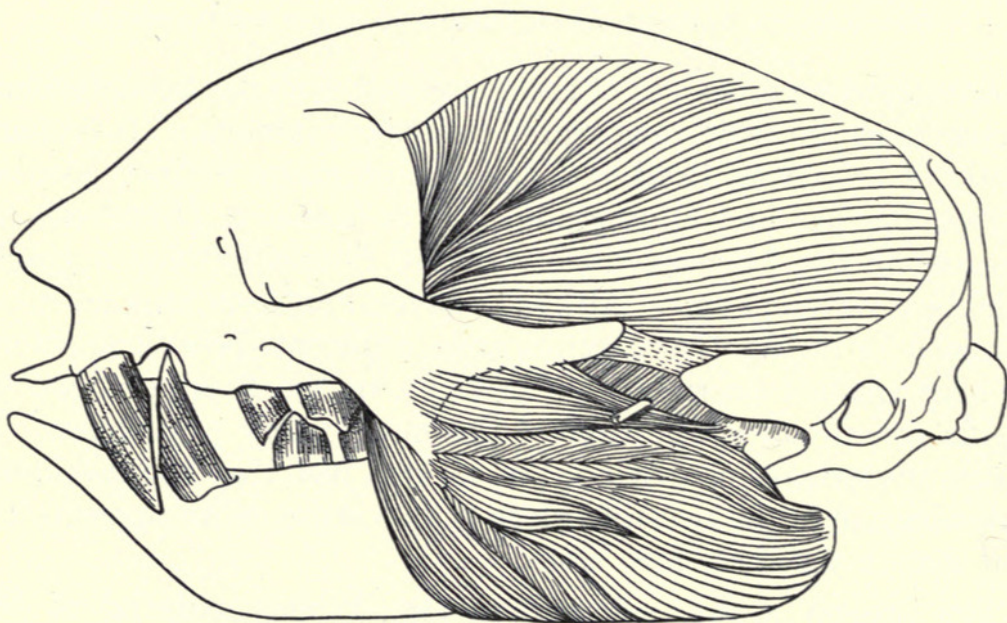


FIG. 23. Superficial muscles of mastication of *Choloepus*.

and Parsons (1889) it is absent in the Bradypodidae. Leche (1896) describes the sterno-mandibular muscle in *Choloepus* and remarks on its absence in *Bradypus*, according to Macalister.

The descriptions of Edgeworth (1935) and Toldt (1908) of the sterno-mandibularis and its development agree in all points. Edgeworth states: "A sterno-hyoideus superficialis is separated from the Rectus cervicis. Its anterior end becomes attached to the transverse aponeurosis of the sterno-hyoidei and so with the digastricus anterior and a sterno-mandibularis is formed. This primary condition is present in *Bradypus* and *Tolypeutes*. It is almost certainly derived from a simple digastric muscle such as is present in Marsupialia. It can be described as a digastric muscle to the transverse aponeurosis of which a sterno-hyoideus superficialis is attached, or a

sterno-mandibularis to the intersection in which the interhyoideus is attached."

Observations of mandibular movements are not recorded in any detail. Beebe (1926) states that he could never see a lateral movement in a *Bradypus* kept for several months as a pet.

OBSERVATIONS

The differences in the masticatory region of the skull between *Choloepus* and *Bradypus* can be summarized as follows:

Choloepus

Mandibular body long, ramus short, angular process weak; condyle in occlusal plane of molars, long and oval; condylar axes oblique, converging posteriorly; articulating surface convex in the medial one-third, concave in the lateral two-thirds.

Descending zygomatic process triangular, short, vertical.

Pterygoid plate narrow, short, posterior part pneumatized.

Articulating surface on temporal bone narrow in antero-posterior, wide in medio-lateral direction.

In the position of rest, the mandibular condyle in contact with the articulating fossa excepting a narrow anterior strip.

Bradypus

Mandibular body short, ramus long, angular process strong; condyle high above occlusal plane of molars, circular, knob-like; articulating surface regularly convex; rough projection on antero-medial circumference for attachment of external pterygoid muscle.

Descending zygomatic process narrow, long, oblique, directed ventrad and posteriorly.

Pterygoid plate wide, long, solid.

Articulating surface on temporal bone wide in antero-posterior direction.

In the position of rest, the mandibular condyle in contact with the anterior part of the articulating fossa only, wide posterior area free.

The muscles of mastication show only insignificant differences in *Choloepus* and *Bradypus* (figs. 23 and 24).

Masseter muscle.—Its origin is restricted to the zygomatic bone. The fibers arise from the anterior and posterior borders and the tip of the descending process and from the lower border of the temporal process. It is inserted to the lower border of the mandible to and including the angular process, and to the outer surface of the ramus. Here the insertion area is extended upward to the mandibular neck. The fibers arising from anterior border and tip of descending process course vertically to the mandible, whereas the fibers of the posterior part of the muscle are horizontal. A division into a superficial and a deep layer is arbitrary and incomplete.

Zygomatico-mandibular muscle.—Origin from zygomatic process of temporal bone and zygomatic ligament, insertion to the outer surface of coronoid process and adjacent area of ramus. Its fibers are directed ventrad and anteriorly.

Temporal and pterygoid muscles are weak. The first shows no peculiarities. The pterygoids arise on the outer surface of the pterygoid plate. The internal pterygoid inserts to the angular process, the external to the mandibular neck.

In the *temporo-mandibular articulation* a disk is missing. The fibrous covering of the condyle is very thick. The capsule is loose.

A *sterno-mandibular muscle* is present in *Choloepus*. The superficial fibers of the sterno-hyoid muscle have lost their attachment to the hyoid bone and are fused by a tendinous inscription to the

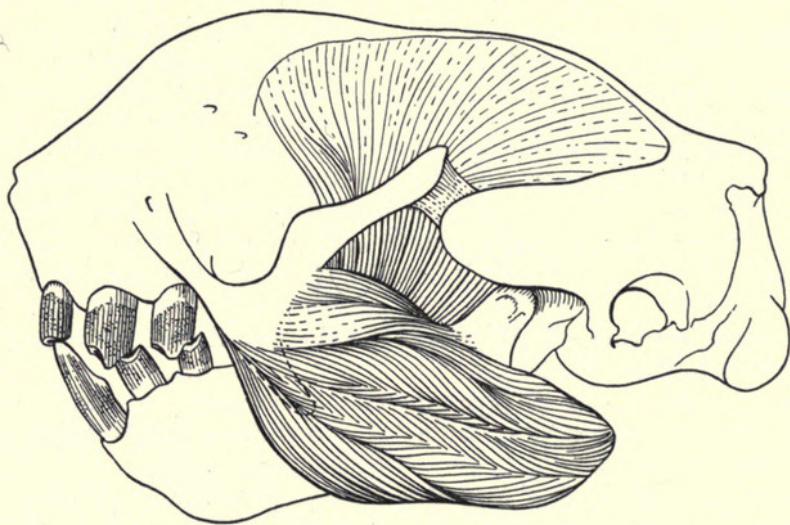


FIG. 24. Superficial muscles of mastication of *Bradypus*.

anterior belly of the digastric muscle. The posterior digastric ends in this tendinous inscription.

In *Bradypus* a sterno-mandibularis is absent. The insertion of the sterno-hyoid muscle to the hyoid coincides with the attachment of the digastric tendon to the same bone.

Dentition.—The smooth glossy attrition facets of the tusk-like first teeth in *Choloepus* are not in contact in the rest position of the jaws. On the “molars” two types of attrition marks can be distinguished: (1) Dull, irregular facets, giving the tooth irregular, pointed “cusps”; (2) glossy narrow facets that originate by sharp contact of the teeth during the masticatory stroke. They are found on the anterior (mesial) edges of the lower and the posterior (distal) edges of the upper teeth (fig. 25A).

In *Bradypus* the first upper tooth is markedly reduced, the first lower tooth chisel-shaped. The larger attrition facet on the lower first tooth is found on its posterior (distal) surface. The glossy

narrow attrition facets on the “molars” show a reversed arrangement compared with that of *Choloepus*. They are seen on the posterior (distal) edges of the lower and on the anterior (mesial) edges of the upper teeth (fig. 25B).

DISCUSSION

The development of a descending zygomatic process in the Bradypodidae is correlated to the change in the fiber direction of the masseter muscle. A considerable part of this muscle assumes a

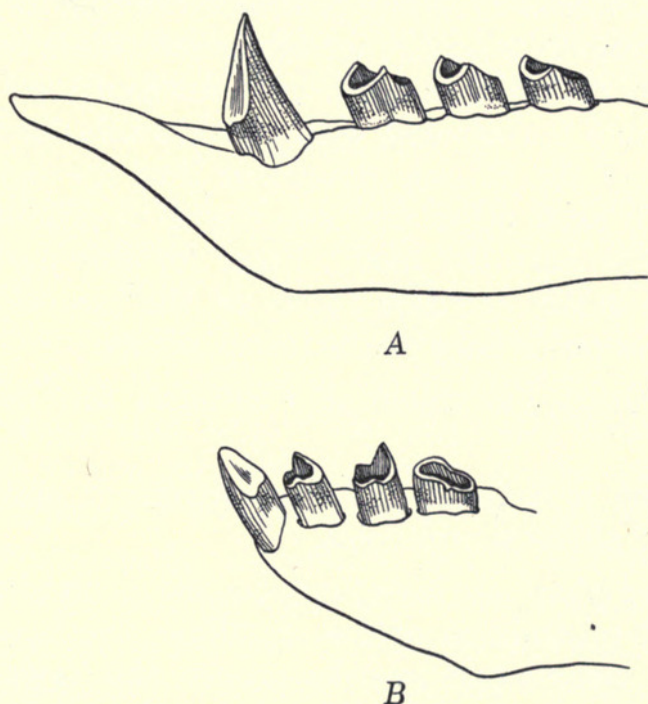


FIG. 25. Lower jaw and teeth of A, *Choloepus*; B, *Bradypus*.

horizontal course from the descending zygomatic process to the upper parts of the mandibular ramus. This portion of the masseter muscle functions as a strong protractor of the mandible. Its action, however, is integrated into the masticatory movement in a strikingly different way in *Choloepus* and *Bradypus*. Although both are phyllophagous, the differences in the development of their anteriormost teeth would indicate a difference in their mode of cutting leaves. Unfortunately, detailed knowledge in this respect is still lacking. In spite of the similarity in the anatomy of the masticatory muscles, the differences in the structure of the mandibular articulation indicate different masticatory movements. A study of the attrition facets gives the final clue to the direction of the masticatory stroke in *Choloepus* and *Bradypus*. A sterno-mandibular muscle as a strong

retractor of the mandible has developed in *Choloepus* and is lacking in *Bradypus*, although *Bradypus* clearly shows an initial stage in the formation of this muscle. The presence or absence of a sterno-mandibularis fits perfectly in the analysis of the masticatory movement of the Bradypodidae. The development of a sterno-mandibularis by a fusion of the superficial fibers of the sterno-hyoid to the anterior digastric adds considerable force to the retracting component of the latter.

In *Choloepus* a function of the shear-like anterior teeth is possible only if the mandible is forcefully protracted during its closing movement. At rest and in a pure hinge movement these teeth are not in contact. When the anterior teeth have finished their cutting function the mandible is retracted with considerable force and it is in this last phase of the closing movement that the upper and lower molars glide on each other and accomplish a grinding movement necessary to masticate the food. Proof for this movement is the location of the glossy attrition facets on the posterior edge of the upper and the anterior edge of the lower molars.

The masticatory movement of *Choloepus* can be divided into three phases:

(1) Opening movement: a hinge movement and the result of the contraction of the suprahoids.

(2) Cutting phase of closing movement: a combination of hinge movement and protraction of the mandible, the result of the contraction of the masticatory muscles proper; the forward component is contributed by the external pterygoid and, mainly, by the horizontal portion of the masseter muscle.

(3) Grinding phase of closing movement: a gliding movement, retraction of the mandible under pressure; the retraction is the function of the sterno-mandibular muscle, the pressure is provided by the vertical fibers of the masseter, temporal and internal pterygoid muscles.

In *Bradypus* the peculiar tusk-like development of the anterior teeth is lacking. They are chisel-shaped, the upper being rather small. The fact that the mandibular condyle is, in the position of rest, in contact with the anterior part of the glenoid fossa only, indicates that a posterior gliding of the mandible plays an important role in the masticatory movement. The masticatory stroke is directed from behind forward, as proved by the location of the glossy attrition facets on the molars. Their position is the reverse of that

in *Choloepus*; they are found on the anterior edge of the upper and on the posterior edge of the lower teeth.

The masticatory movement of *Bradypus* exhibits two phases:

(1) Opening movement: a combination of hinge movement and retraction, the result of the contraction of the suprahyoids; the posterior gliding component is contributed by the digastric muscle acting without great force.

(2) Closing movement: the grinding masticatory stroke, a combination of hinge movement and protraction of the mandible, is the result of the contraction of the masticatory muscles; the anterior gliding component is contributed by the external pterygoid and, mainly, by the horizontal portion of the masseter muscle.

SUMMARY

(1) The development of a descending zygomatic process in *Choloepus* and *Bradypus* is correlated with the development of a strong horizontal portion of the masseter muscle in both.

(2) The insertion of the horizontal bundles of the masseter is extended high up to the region of the mandibular neck.

(3) The protracting force of the horizontal fibers of the masseter, synergistic to the external pterygoid muscle, plays a different role in the masticatory movement in *Choloepus* and *Bradypus*.

(4) In *Choloepus* the horizontal part of the masseter assures contact between the cutting "canines" during the first closing phase. In the second, grinding phase of the closing movement the mandible is forcefully retracted by the sterno-mandibular muscle.

(5) In *Bradypus* the mandible is retracted during the opening phase by the digastric muscle, the condyle gliding into the posterior part of the wide glenoid fossa. At the end of the closing phase the horizontal part of the masseter effects the grinding movement by protracting the mandible with great force.

(6) The presence of glossy attrition facets on opposite edges of the molars in *Choloepus* and *Bradypus* proves that the grinding movement occurs in opposite directions in these two animals.

REFERENCES

BEEBE, WILLIAM

1926. The Three-Toed Sloth, *Bradypus Cuculliger Cuculliger* (Wagler). *Zoologica*, 7, pp. 1-67.

EDGEWORTH, F. H.

1935. *The Cranial Muscles of Vertebrates*. Cambridge University Press.

LECHE, WILHELM

1874-1900. Muskulatur. Bronn's Klassen und Ordnungen des Tierreiches. Mammalia, 1, pp. 649-919.

LUBOSCH, WILHELM

1908. Das Kiefergelenk der Edentaten und Marsupialier. Denksch. med. naturw. Ges. Jena, 7, 519-555.

SCHULMAN, HJALMAR

1906. Vergleichende Untersuchungen über die Trigeminusmuskulatur der Monotremen. Denksch. med. naturw. Ges. Jena, 6, pp. 297-400.

TOLDT, C. VON

1908. Der vordere Bauch des *M. digastricus mandibulae* und seine Varietäten beim Menschen. II. Sitz. Akad. Wiss. Wien, (3), 117, pp. 229-321.

WINDLE, B. C. A., and PARSONS, F. G.

1899. On the Myology of the Edentata. Proc. Zool. Soc. Lond., 1899, pp. 314-339, 990-1017.



Sicker, Harry. 1944. "Masticatory apparatus of the sloths." *Masticatory apparatus of the sloths* 29, 161–168.

View This Item Online: <https://www.biodiversitylibrary.org/item/20861>

Permalink: <https://www.biodiversitylibrary.org/partpdf/24017>

Holding Institution

University Library, University of Illinois Urbana Champaign

Sponsored by

University of Illinois Urbana-Champaign

Copyright & Reuse

Copyright Status: In copyright. Digitized with the permission of the rights holder.

Rights Holder: Field Museum of Natural History

License: <http://creativecommons.org/licenses/by-nc-sa/3.0/>

Rights: <https://biodiversitylibrary.org/permissions>

This document was created from content at the **Biodiversity Heritage Library**, the world's largest open access digital library for biodiversity literature and archives. Visit BHL at <https://www.biodiversitylibrary.org>.