

[COMMUNICATION]

Tooth Development and Replacement in the Japanese Greater Horseshoe Bat, *Rhinolophus ferrumequinum nippon*

KIMITAKE FUNAKOSHI¹, YUKO FUKUE² and SHOJI TABATA³

¹Biological Laboratory, Kagoshima Keizai University, Kagoshima 891-01,

²Department of Biology, Faculty of Science, Kagoshima University 890, and

³Department of Oral Anatomy, Kagoshima University Dental School, Kagoshima 890, Japan

ABSTRACT—The dental formula of the deciduous teeth in *Rhinolophus ferrumequinum nippon* was $i1/2\ c1/1\ p2/3 \times 2 = 20$. All the germs of deciduous teeth were present in the fetuses of 7–8 weeks. The deciduous teeth, exclusive of the p_3 , attained their maximal size at 9–10 weeks, and then odontoclasts appeared in the dental pulp and began to resorb the dentin. The resorption and exfoliation of the teeth have completed at birth. The typical sequence of resorption of the deciduous teeth was $i_1, i_2, c_1, c^1, p^2, p_2, i^2, p^4, p_4$. On the other hand, the p_3 appeared late, developed slowly, and was remained in a small size, while the tooth germ of the P_3 was degenerating. The permanent teeth began to erupt at birth, and the usual sequence of their eruption was $I_1, I_2, C^1, C_1, P_4, P^4, (P_2, M_1, M_2, M^1, M^2), M_3, M^3, (I^2, P^2, p_3)$. The incidence of lack of the p_3 was 13.2, 5.3 and 5.3% for the left, right and both sides of the jaw, respectively. Such a congenital abnormality suggests that the p_3 is genetically undergoing a process of degeneration.

INTRODUCTION

Unlike deciduous teeth of most mammals, those in the Chiroptera are not functional in feeding. In most bat species, however, the deciduous teeth are highly specialized, strikingly different from the permanent ones, and used by the young in clinging to the maternal nipple [1–11]. On the other hand, in at least four genera, *Rhinolophus* (Rhinolophidae), *Lavia* (Megadermatidae), *Hipposideros* and

Triaenops (Hipposideridae), all the deciduous teeth are resorbed or exfoliated prior to birth [12–14], and in *Tadarida* (Molossidae) some of them are also resorbed prenatally [15]. Reasons for such differences are not clear, but it has been suggested that the young in such genera are for some reasons in less need of the deciduous teeth after birth [3].

From an evolutionary or phylogenetic point of view, such deciduous dentition and its replacement would be of interest to study. However, there have been few reports which dealt with the sequential resorption and histological changes of the deciduous teeth in bats [14]. The present study was therefore carried out to examine histological changes of the deciduous teeth in the Japanese greater horseshoe bat, *Rhinolophus ferrumequinum nippon*.

MATERIALS AND METHODS

A total of 34 (14 pregnant females and 20 young males) were collected at the tuffaceous cave of Katano-dô in Kagoshima Prefecture during the period from May to August in 1988. On the day of capture, the fetuses were taken out from the mothers under ether anesthesia, weighed, measured of the lengths of skull and forearm, and sexed (see Table 1). The age of each fetus or young was determined on the basis of the assumptions that in *R. f. nippon*, fertilization would have occurred on ~3 April [16], and the greatest length of the skull would have increased at a rate of 0.32 mm per day

Accepted December 26, 1991

Received October 11, 1991

² Present address: Department of Biology, Faculty of Science, Kanazawa University, Kanazawa 920, Japan.

TABLE 1. External measurements, body weights and estimated age of fetus in *R. f. nippon*.

Date captured	Fetus	Sex	Greatest length of skull (mm)	Forearm length (mm)	Body weight (g)	Estimated age of fetus in weeks**
29 May	5PE	♂	10.1	7.7	0.89	7
29 May	5PY	♂	11.1	7.4	1.03	8
29 May	5JJ	♂	11.5	8.5	1.18	8
29 May	5PB	♂	11.5	8.8	1.25	8
29 May	5PC	♀	11.6	8.3	1.26	8
11 June	6PD	♂	14.3	11.3	2.40	9
11 June	6PZ	♀	14.5	12.2	2.66	9
11 June	6PU	♀	15.5	13.7	3.16	10
11 June	6PL	♂	15.8	14.6	3.61	10
11 June	6PW	♂	16.2	14.5	3.90	10
26 June	6PT	♂	18.5	18.0	4.75	11
26 June	6PC	♀	18.6	20.7	5.52	11
26 June	6PB	♂	19.5	24.2	6.72	11
26 June	6PH*	♂	21.0	28.5	7.58	12

* Newborn young shortly after birth.

** Estimated from the presumed day (~3 April) of fertilization [16].

on and after the 3rd week [17].

Of 14 fetuses, 8 were fixed in 10% formalin and their skulls were decalcified in Plank-Rychlo's fluid, embedded in Sorvall embedding medium PN 45582 (DuPont Comapny, Connecticut). Transverse serial sections (3 μ m) for light microscopy were stained with Mayer's hematoxylin and eosin. Six fetuses were fixed in 80% ethanol and their skulls were stained with alucian blue 8GS and alizarin red S. Cartilaginous tissues are stained deeply blue with the former, while bone and teeth are stained deeply red with the latter. The deciduous teeth were observed using a binocular microscope. Adult females or young males ranging from newborn to volant sizes were fixed in 10% formalin and transferred to 70% ethanol; their teeth were observed *in situ* using a binocular microscope. The tooth nomenclature used here was followed by that of Miller [2]. Uppercase letters signify permanent teeth and lowercase letters, deciduous ones; numbers indicate tooth positions in the upper or lower jaw (e.g. P² or P₂ respectively). The dental formula of permanent teeth in *R. f. nippon* has been known as follows [18]: I1/2 C1/1 P2/3 M3/3 $\times 2 = 32$.

RESULTS

Development and resorption of deciduous teeth

The dental formula of the deciduous dentition in the Japanese greater horseshoe bat was found as, i1/2 c1/1 p2/3 $\times 2 = 20$. In the fetuses of the 7th or 8th week, all the germs of the deciduous teeth were observed in the upper and lower jaws (Figs 1A, B and 2A-E). In these deciduous tooth germs, predentin or dentin has been formed with the exception of p₃. The p₃ appeared later in the development and was still in the cap or bell stage at the 8th week (Fig. 2E). The dental laminas of permanent teeth were already present in the alveoli lingually to the deciduous teeth. Especially, the P₂ developed just below the p₂ and was in the cap stage at the 8th week (Fig. 2D).

At the 9–10th week, the deciduous teeth, exclusive of the p₃, attained their greatest size (0.05–0.34 mm long), moved upward, and located in the tissue just over the permanent teeth. The deciduous incisors (i², i₁ and i₂) were simple in shape, that is, ovoid in the longitudinal section of the teeth (Figs 1C, D and 2F). The deciduous canines (c¹ and c₁) were relatively small, with the

crowns being only slightly larger than those of the deciduous incisors (Figs 1C, D and 2G). The deciduous premolars (p^2 , p^4 , p_2 , p_3 and p_4) had roughly triangular and recurved crowns (Figs 1C,

D and 2H-J). The p_3 (0.19 mm long) was rooted at the upper-labial edge of the alveolus, and many odontoblasts were observed along the margin of the dental pulp (Fig. 2I). Calcification of the

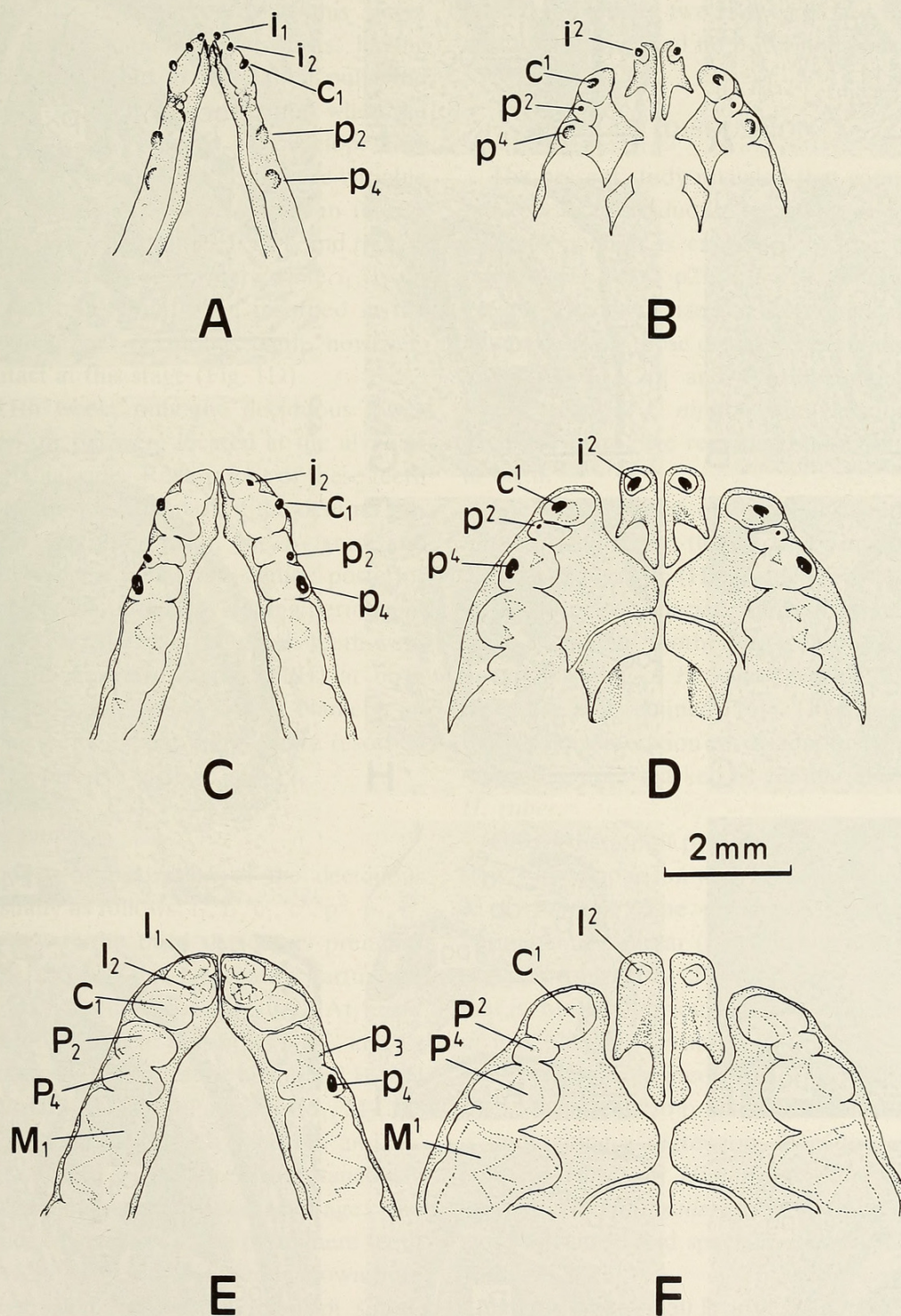
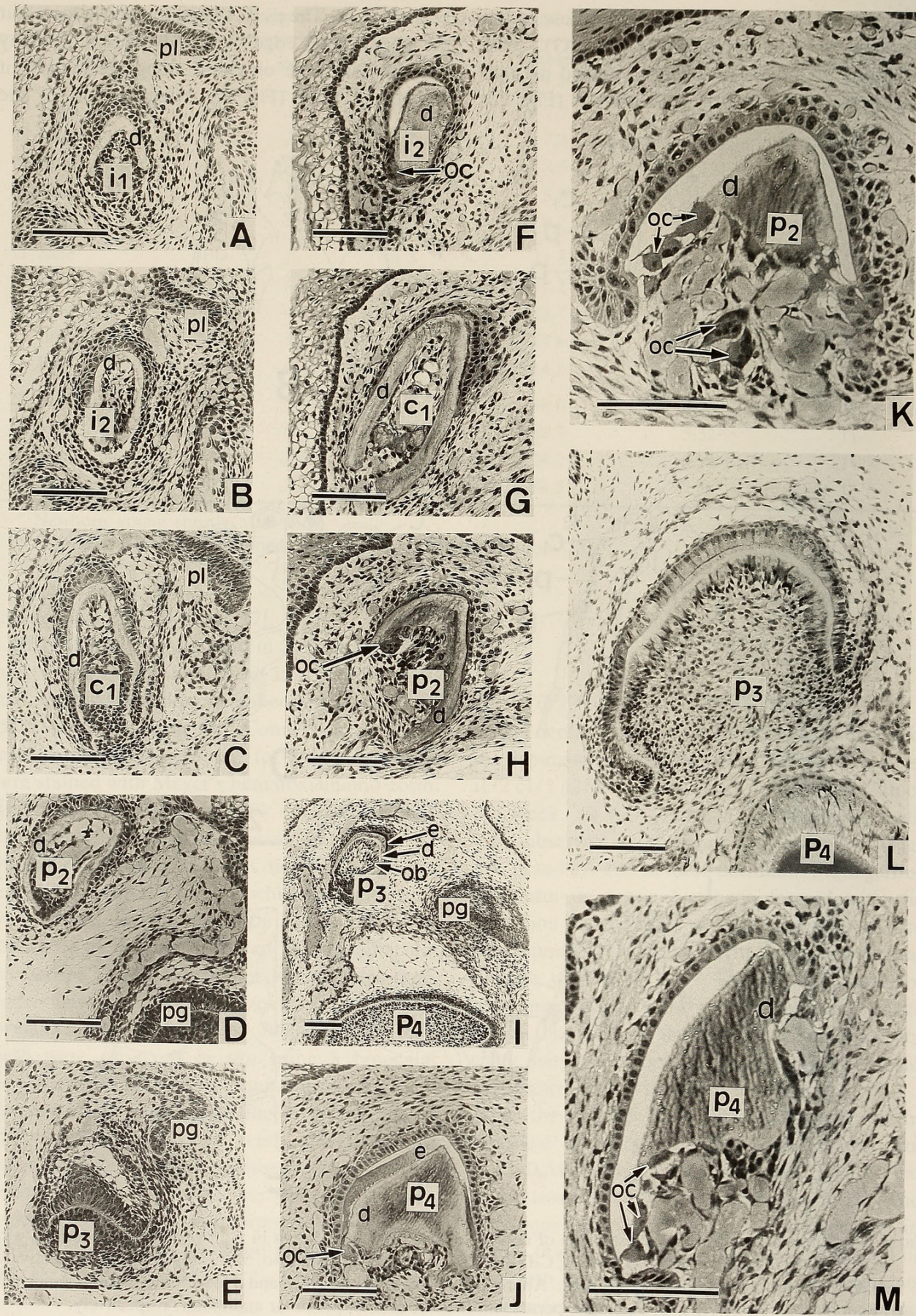


FIG. 1. Diagrams showing the occlusal view of deciduous and permanent teeth in *R. f. nippon* after staining with alucian blue 8GS and alizarin red S. A-B, C-D and E-F, based on specimen No. 5PY, 6PD and 6PT, respectively. A, C, E, lower jaws; B, D, F, upper jaws. Abbreviations in Figs 1 and 2: i, c and p, deciduous incisor, canine and premolar, respectively. I, C, P and M, permanent incisor, canine, premolar and molar, respectively.



dentin and enamel in the p_3 was also in progress because of their darker staining with hematoxylin and eosin. On the other hand, the tooth-germ of the P_3 became degenerated. In other deciduous teeth, calcification did not occur at this stage. Larger and deeply-staining odontoclasts, having several nuclei, appeared in the dental pulp and destroyed and resorbed the root dentin when the permanent tooth germ began to develop (Fig. 2F-H, J). Degrees of the resorption were variable in different individuals. For example, in fetuses 6PD and 6PZ (9th week), the left i_1 , i_2 and right i_1 had been resorbed in the former, while i_1 , i_2 on both sides and left c_1 had been resorbed in the latter. All the upper deciduous teeth, however, were still intact at this stage (Fig. 1D).

At the 11th week, only the deciduous lower premolars (p_2 or p_4) were located at the alveolar crest on the labial side. Resorptions of these teeth progressed in considerable part of the dentin (Fig. 2K, M). On the other hand, the p_3 grew and located in the upper, labial and slightly posterior region of the alveoli in the developing permanent premolar (P_4) (Fig. 2L). No deciduous teeth were observed in the newborn young (6PH) at birth (12th week) and other young males. Namely, all the deciduous teeth, except the p_3 , were resorbed and exfoliated prior to birth.

Tooth replacement

The sequence of resorption of the deciduous teeth was usually as follows: i_1 , i_2 , c_1 , c^1 , p^2 , p_2 , i^2 , p^4 , p_4 . However, the third deciduous premolar (p_3) was not resorbed but remained. Parturition occurred from late June to early July. At birth, permanent teeth began to erupt. I_1 , I_2 , C^1 and C_1 appeared within 1–2 weeks after birth, and P_4 and P^4 followed. At 3–4 weeks of age, P_2 , M_1 , M_2 , M^1 and M^2 erupted simultaneously, and M_3 and M^3 followed. I^2 , P^2 and p_3 appeared simultaneously during the weanling period of 5 weeks of age. The usual sequence of eruption of the permanent teeth was shown as follows (groups of teeth shown here in parentheses were considered to erupt simul-

taneously): I_1 , I_2 , C^1 , C_1 , P_4 , P^4 , (P_2 , M_1 , M_2 , M^1 , M^2), M_3 , M^3 , (I^2 , P^2 , p_3).

Congenital abnormalities in the dentition of the bat were found. Of 38 specimens, five (13.2%) lacked the left p_3 , two (5.3%) lacked the right p_3 , and two (5.3%) had no p_3 on both sides.

DISCUSSION

The present study revealed that complete number of the deciduous teeth in *R. f. nippon* (Rhinolophidae) is expressed by the dental formula of $i1/2 c1/1 p2/3 \times 2 = 20$. These teeth are greatly reduced in size and less complex in form as compared with those of the Vespertilionidae [2, 5, 6, 8, 12, 19, 20] and Phyllostomidae [2, 11]. Further, in *R. f. nippon*, the deciduous teeth, exclusive of p_3 , are resorbed and exfoliated prior to birth.

The development of deciduous teeth in *R. f. nippon* is similar to that in *Hipposideros ruber* or *Triaenops persicus* (Hipposideridae) [14], though in the latter two species, the resorption process in each deciduous tooth is as yet unknown. In a newborn young of *H. ruber*, two small deciduous teeth are still retained [14]. Thus, it is assumed that the degeneration of deciduous teeth in *R. f. nippon* is more marked as compared with that in *H. ruber*.

The formation of p_3 begins later and it develops slowly in comparison with other deciduous teeth in *R. f. nippon*. The p_3 is not replaced by the permanent premolar (P_3) which is degenerating, and the p_3 erupts last. The congenital abnormality, that is, loss of p_3 is found in *R. f. nippon*. The rate of loss (23.7%) is similar to that (20.4%) in the same species examined in Nagano Prefecture [21]. These facts seem to provide a evidence that the p_3 is undergoing a regression, from the evolutionary point of view. In *Hipposideros* the p_3 or P_3 is missing [2]. *Hipposideros* seems to be genetically more advanced and specialized form than *Rhinolophus* [22, 23].

Similarly, the small P^2 in *R. f. nippon* developed

FIG. 2. Cross sections through the lower jaw in *R. f. nippon*, showing deciduous and developing permanent teeth after staining with Mayer's haematoxylin and eosin. A-E, F-J and K-M, obtained from specimens No. 5JJ, 6PU and 6PB, respectively. d, dentin; e, enamel; ob, odontoblast; oc, odontoclast; pg, permanent tooth germ; pl, permanent dental lamina. Scale bar, 0.1 mm.

slowly and erupted late, and was missing in 5 out of 54 specimens (9.3%) [21], while none of the specimens examined here lost the P².

The deciduous teeth of the Phyllostomidae are generally smaller in size and morphologically less complex than those of the Vespertilionidae and Molossidae [2, 11, 24]. The size and shape of deciduous teeth seem to correlate with the maternal care pattern in the bat. It has been suggested that the increased complexity in the deciduous dentition of vespertilionids may facilitate for the young to grasp the mother rather than to maintain a hold on the nipple after clinging to the mother [25]. On the other hand, in rhinolophids and hipposiderids, the young are not left alone but are attaching to the mother at the roost all through the day. Such young behavior and parental care in rhinolophids and hipposiderids may not so strongly require the deciduous teeth for the young to grasp the mother as do those in vespertilionids and molossids.

Eruption of the permanent teeth in *R. f. nippon* begins after the exfoliation of the deciduous teeth excluding the p₃ has ended. The eruption, however, is not necessarily associated with the exfoliation of their deciduous counterparts, though this is true for the lower incisors. The development of the permanent teeth in *R. f. nippon*, particularly I₁, I₂, C¹ and C₁, is rapid as well as in *H. ruber* [14], and they erupt earlier than those in most bat families. Therefore, the erupted permanent teeth may permit, to some extent, for the young to hold on their mother's nipples or on the false ones existing on the lower part of the abdomen, in place of the deciduous teeth.

ACKNOWLEDGMENTS

We wish to thank Prof. T. Semba of Kagoshima University Dental School, and Prof. M. Hotta and Dr. S. Yamane of Kagoshima University for their warm encouragement and the use of their facilities, and to Drs. K. Wada and T. Nakama of Kagoshima University Dental School for their valuable advice and discussions during the course of this study.

REFERENCES

- 1 Miller, G. S. (1896) Proc. Biol. Soc. Washington, **10**: 113-114.
- 2 Miller, G. S. (1907) Bull. U. S. Nat. Mus., **57**: 1-282.
- 3 Allen, G. M. (1939) Bats. Harvard Univ. Press, Cambridge, pp. 1-368.
- 4 Matthews, L. H. (1950) Mammalia, **14**: 11-13.
- 5 Reeder, W. G. (1953) Mus. Zool. Univ. Mich., **545**: 1-3.
- 6 Stegman, L. C. (1956) J. Mamm., **37**: 58-63.
- 7 Friant, M. (1963) Acta Anat., **52**: 90-101.
- 8 Fenton, M. B. (1970) Can. J. Zool., **48**: 817-820.
- 9 Orr, R. T. (1970) In "Biology of Bats, I". Ed. by W. A. Wimsatt, Academic Press, New York, pp. 217-231.
- 10 Slaughter, B. H. (1970) In "About Bats". Ed. by B. H. Slaughter and D. W. Walton, Southern Methodist Univ. Press, Dallas, pp. 51-83.
- 11 Phillips, C. J. (1971) Misc. Publ. Mus. Nat. Hist., Univ. Kansas, **54**: 1-138.
- 12 Spillmann, Fr. (1927) Abhandl. Senckenbergischen Naturforschenden Gesellschaft, Frankfurt A. M., **40**: 249-255.
- 13 Dorst, J. (1953) Mammalia, **17**: 83-84.
- 14 Hermanson, J. W., Woods, C. A. and Howell, K. M. (1982) J. Mamm., **63**: 527-529.
- 15 Dorst, J. (1957) Mammalia, **21**: 133-135.
- 16 Oh, Y. K., Mori, T. and Uchida, T. A. (1985) J. Reprod. Fert., **73**: 121-126.
- 17 Fukue, Y. (1989) Unpublished graduation thesis. Fac. Sci. Kagoshima Univ., pp. 1-39 (in Japanese).
- 18 Imaizumi, Y. (1970) The Handbook of Japanese Land Mammals. Shin-shicho-sha, Tokyo, pp. 1-350 (in Japanese with English description).
- 19 Dorst, J. (1949) Mammalia, **13**: 45-48.
- 20 Morii, R. (1976) J. Mamm. Soc. Japan, **6**: 248-258 (in Japanese with English abstract).
- 21 Miyao, T. (1973) J. Mamm. Soc. Japan, **5**: 230-233 (in Japanese with English abstract).
- 22 Ando, K. (1982) Unpublished Ph. D. thesis. Fac. Agr. Kyushu Univ., pp. 1-359 (in Japanese with English summary).
- 23 Yoon, M. H. and Uchida, T. A. (1983) J. Fac. Agr., Kyushu Univ., **28**: 135-146.
- 24 Phillips, C. J., Grimes, G. W. and Forman, G. L. (1977) In "Biology of Bats of the New World Family Phyllostomatidae. Part II". Ed. by R. J. Baker, J. K. Jones, Jr. and D. C. Carter, Spec. Publ. Mus. Texas Tech Univ., Lubbock, pp. 121-246.
- 25 Kleiman, D. G. and Davis, T. M. (1979) In "Biology of Bats of the New World Family Phyllostomatidae. Part III." Ed. by R. J. Baker, J. K. Jones, Jr. and D. C. Carter, Spec. Publ. Mus. Texas Tech Univ., Lubbock, pp. 367-402.

1 Miller, G. S. (1896) Proc. Biol. Soc. Washington,



Funakoshi, Kimitake, Fukue, Yuko, and Tabata, Shoji. 1992. "Tooth Development and Replacement in the Japanese Greater Horseshoe Bat, *Rhinolophus ferrumequinum nippon*(COMMUNICATION)(Developmental Biology)." *Zoological science* 9, 445–450.

View This Item Online: <https://www.biodiversitylibrary.org/item/125372>

Permalink: <https://www.biodiversitylibrary.org/partpdf/71527>

Holding Institution

Smithsonian Libraries and Archives

Sponsored by

Biodiversity Heritage Library

Copyright & Reuse

Copyright Status: In Copyright. Digitized with the permission of the rights holder.

License: <http://creativecommons.org/licenses/by-nc-sa/3.0/>

Rights: <https://www.biodiversitylibrary.org/permissions/>

This document was created from content at the **Biodiversity Heritage Library**, the world's largest open access digital library for biodiversity literature and archives. Visit BHL at <https://www.biodiversitylibrary.org>.