Z. Säugetierkunde 56 (1991) 65–71

ISSN 0044-3468

Comparative gut morphometrics of Vervet *(Cercopithecus aethiops)* and Samango *(C. mitis erythrarchus)* monkeys

By M. R. Bruorton and M. R. Perrin

Department of Zoology and Entomology, University of Natal, Pietermaritzburg, South Africa

Receipt of Ms. 2. 5. 1990
Acceptance of Ms. 18. 9. 1990

Abstract

A comparative morphometric examination of the gastrointestinal tracts of vervet *(Cercopithecus aethiops* and samango *C. mitis erythrarchus* monkeys revealed that samangos possess significantly larger volumes in the hindgut (caecum and colon). The surface area of the main absorptive region of the gastrointestinal tract (the small intestine) was also larger in samangos than in vervets. Samangos include larger amounts of fibrous leaf material in their diets than vervets, and the importance of the larger volumes are discussed with reference to the fermentative process required to digest and utilise this foliar component.

Introduction

The structure of the gastrointestinal tract (GIT) is fairly homogeneous among different orders of mammals (Chivers and Hladik 1980), and development of different parts of the GIT generally reflect adaptations to different foods. Plant food with a high content of structural carbohydrates can be digested with the help of microbes in either the stomach or the hindgut, where the enzymes produced by the microbes degrade the food and render its chemical constitutents absorbable (Langer 1988). Among the African primates are examples of both foregut (stomach) and hindgut (caecum and colon) fermenters. The folivorous colobines possess plurilocular, haustrated stomachs, while most of the frugivorous/omnivorous cercopithecines possess simple unilocular, glandular stomachs (Langer 1988), a well-developed caecum and a large and haustrated colon.

The gross morphology and ultrastructure of the GIT of vervet monkeys *(Cercopithecus aethiops)* and samango monkeys *(C. mitis)* is similar (Bruorton 1989). Samangos are frugivorous, but include a relatively high proportion of leaves in their diets (Rudran 1978; Cords 1987; Lawes 1990), while vervets are generally regarded as frugivorous/omnivorous and consume roughly equal proportions of fruit and animal (mostly insect) material (Dunbar and Dunbar 1974; Kavanagh 1978; Watson 1985). GIT morphology may show considerable variation even between frugivorous primate species, depending on the amount of insects or leaves included in the primarily fruit diet (Chivers and Hladik 1980), and this may include expansion within the tract. This is usually associated with the fermentation process, since the larger the volume, the more fermentation can occur (Chivers and Hladik 1980).

A comparative examination was initiated to determine whether the volumes of various regions of the gastrointestinal tract (and surface area of small intestine) differ significantly between the two primate species. Volumes are indicators of physiological processes, such as microbial digestion, that are important in herbivore nutrition. This comparative examination might therefore assist in providing an explanation of the digestive strategies of the two species, and in determining how samangos digest the foliar components of their diet.

U.S. Copyright Clearance Center Code Statement: 0044-3468/91/5602-0065 $ 02.50/0

Materials and methods

Nine vervet monkeys (4 adult males, 5 adult females) and eight samangos (4 adult males, 4 adult females) were shot on the farm Braco in the Karkloof area of Natal and used in this examination. Animals were weighed in the field and body lengths were measured from tip of nose to tip of tail. Gastrointestinal tracts were removed immediately. These were examined in the laboratory 2–3 hours later, which allowed for complete relaxation of the musculature in the GIT wall. No specimens were fixed prior to measuring, as this can cause distortion of the tract wall.

Measurements of the stomach, small intestine, caecum and colon, completely cleared of all mesenteric tissue, were made in a water-filled 2 m × 0.5 m × 0.1 m basin. Measuring the length of the gut under water minimises stretching, and is especially important when measuring small intestinal length. Small and large intestines were treated as cylinders and volumes were calculated from mean measurements of length and circumference. Width varies along the length of intestine, and at least 5 measurements of width (of intact tissue) were taken at regular points along the length. At a calculated mean width the tissue was opened and the circumference was measured. The surface area of the small intestine was also calculated from length and circumference measurements.

To calculate the volume of the caecum, an incision was made dorsally from the ileocaecal junction to the apex of the caecum. The contents were then flushed out and the lateral walls of the caecum were flattened into an approximate cylindrical shape. The length measurement and average circumference could then be taken and the volume calculated as for the colume of a cylinder.

Accurate measurements of stomach volume were difficult to obtain, largely as a result of its irregular shape and size in different animals. In most animals the length of the intact stomach was measured. It was then opened up along the lesser curvature from the gastro-oesophageal opening to the pyloric sphincter, and the incision was extended dorsocranially along the greater curvature for approximately 3 cm (Fig.). The stomach could then be opened out (flattened), the circumference measured and the volume calculated as for the volume of a cylinder.

Two other methods used, a. estimation of stomach volume by filling it with water and b. calculation of stomach volume from the greater curvature measurement (Chivers and Hladik 1980), were found to be unacceptable and were discontinued. Previous comparative work on primate GIT morphometrics involved use of length and width measurements of intact organs (Jones 1970; Milton 1981). Preliminary work in this study included this method, but these measurements were found to be unacceptable. Firstly, the varying thickness of gut musculature means that simple width measurements are mostly inaccurate (often by more than 1 cm). Secondly, the degree of stomach (or intestinal) fill, or the time elapsed since feeding, mean that stomachs of essentially similar size can provide very different measurements depending on when (time of day) they were collected. It is essential that measurements be taken only of dissected sections of the GIT with the contents removed. This negates the effects of varying muscle thickness (because measurements are taken on the mucosal surface of the gut), and is likely to provide more consistent results independent of whether the animal has recently fed or not.

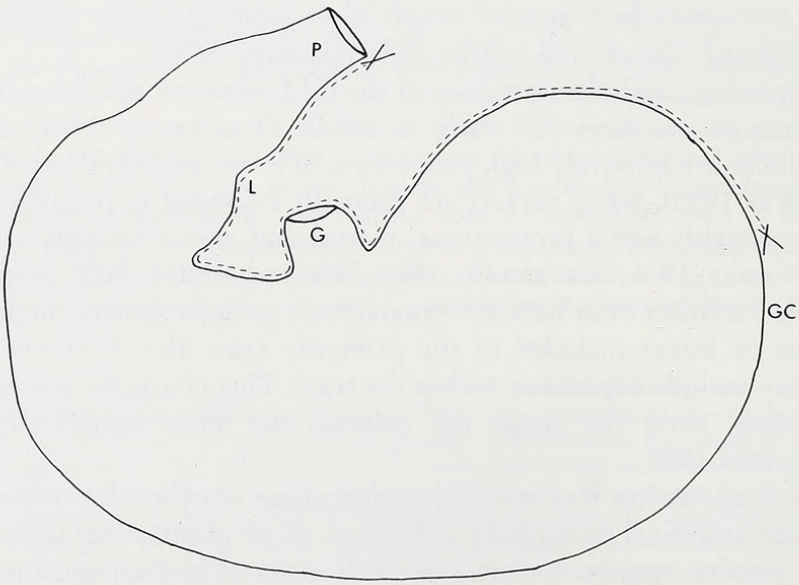

Diagrammatic representation of a stomach, showing the incision made before stomach is opened out (flattened) and measured. P = pyloric sphincter, L = lesser curvature (gastro-oesophageal opening to pyloric sphincter), G = gastro-oesophageal opening, GC = greater curvature (gastro-oesophageal opening to pyloric sphincter)

To compensate for the effect of the larger body size of samangos, volumes of regions of the GIT in each animal were divided by the metabolic live mass ($mass^{0.67}$) of that animal. This provides a ratio that enables direct statistical comparison between species of the volumes of specific regions of the gut. Data were analysed using the Mann-Whitney two sample rank testing procedure (ZAR 1974).

Results

Table 1 compares the measurements of volumes of stomach, small intestine, caecum and colon of adult (male and female) samangos and vervets. The mean body mass of samangos significantly ($P < 0.05$; Mann-Whitney U) exceeds that of vervets (males 8.33 kg : 5.58 kg; females 4.93 kg : 3.82 kg). Table 2 presents gut volumes corrected for differences in body mass of the two species, and includes significant differences in GIT volumes.

Table 3 shows small intestinal surface areas of males and females in each of the two species, and includes significant differences in the surface areas, corrected for different body mass, between the two species.

Table 1. **Measurements of body length and mass, and of volumes of stomach, small intestine, caecum and colon in samango and vervet monkeys**
(Mean ± standard deviation)

	Length (cm)	Mass (kg)	Volume (cm^3) Stomach	SI	Caecum	Colon
Samango						
Adult males (n = 4)	143 ± 1.5	8.3 ± 0.3	265 ± 16	366 ± 45	106 ± 15	728 ± 62
Adult females (n = 4)	121 ± 2.1	4.9 ± 0.3	169 ± 27	325 ± 27	72 ± 5.4	642 ± 99
Vervet						
Adult males (n = 4)	109 ± 1.4	5.6 ± 0.5	194 ± 44	179 ± 54	34 ± 3.1	318 ± 53
Adult females (n = 5)	99 ± 1.6	3.8 ± 0.3	168 ± 24	148 ± 41	23 ± 8.4	179 ± 13

SI = Small intestine.

Table 2. **GIT volumes corrected for differences in body mass between samangos and vervets**
Volume of section of tract/metabolic mass of the animal. (Mean ± standard deviation)

	Volume (cm^3) Stomach	SI	Caecum	Colon
Adult males				
Samango (n = 4)	64.3 ± 3.3	88.5 ± 9.9[a]	25.8 ± 4.2[ab]	175.8 ± 12.9[ac]
Vervet (n = 4)	61.0 ± 10	56.0 ± 13.5[a]	10.8 ± 0.5[ac]	100.5 ± 13.9[ad]
Adult females				
Samango (n = 4)	58.3 ± 7.9	111.8 ± 11.6[ab]	24.5 ± 1.3[cd]	220.0 ± 29.1[d]
Vervet (n = 5)	68.4 ± 8.0	60.2 ± 15.8[b]	9.2 ± 3.1[bd]	73.2 ± 6.6[cd]

Values with common superscripts in columns differ significantly using Mann-Whitney U ($P < 0.05$); SI = Small intestine.

Table 3. **The mean surface area of the small intestine in samango and vervet monkeys, including correction for the different body mass of the species**
(Mean ± standard deviation)

Species			Surface area (cm^2) actual	Surface area (cm^2) corrected
Samango	male	(n = 4)	1163 ± 122	281 ± 27[a]
	female	(n = 4)	1111 ± 48	382 ± 26[ab]
Vervet	male	(n = 4)	692 ± 87	217 ± 21[a]
	female	(n = 5)	595 ± 92	242 ± 33[b]

Values with common superscripts differ significantly using Mann-Whitney U ($P < 0.05$).

Discussion

Vervets and samangos occur syntopically in the Karkloof, and the same food resources were therefore available to both species. This was considered important because of the propensity of the gastrointestinal tract to undergo adaptive changes in relation to forage quality in different areas. These adaptive changes related to dietary variation are well documented (Poksey and Schneeman 1983; Gross et al. 1985; Perrin 1987). Similarly, in this study it was noted that culled vervets from marginal habitats had stomachs which were significantly smaller than those from the Karkloof area. It therefore seems important that comparative GIT measurements be taken on species occurring in sympatry, where the effects of food quality in different habitats would not affect gut morphology or capacity, and where different species are able to specialise on their preferred diets.

Only adult animals were used to obtain the comparative morphometric data. (There were large variations in intraspecific measurements of juvenile and subadult age-classes.) The importance of different organs might vary according to animal age and organ function (Johnson and McBee 1970; Bruorton and Perrin 1988), and it was concluded that only GIT measurements from adult animals would provide consistent and valid results.

There were no significant differences in stomach volumes between the two species. Both have a simple unilocular glandular stomach (Bruorton and Perrin 1988), which is characteristic of Old World cercopithecines (Hill 1958, 1966). On the basis of their similar morphology and function, it is perhaps to be expected that minimal size variations should occur between the two. Milton (1981) showed that stomach size of two sympatric primates in Panama, one highly folivorous *(Alouatta palliata)* and one highly frugivorous *(Ateles geoffroyi)*, were approximately equivalent. This is supported (for *Alouatta* and *Ateles*) by Hladik (1967) in his work on the relative surface area of sections of the digestive tracts of 24 primate species. Schieck and Millar (1985) showed that it is the distal parts of the digestive tract (caecum and colon) that correctly indicate diet type within rodent families. It appears, therefore, that stomach volumes remain fairly constant relative to body weight within primates possessing simple stomachs, and that differences in GIT volumes related to dietary adaptations would be found in other sections of the digestive tract.

Significant differences in small intestinal surface area existed between both males and females of the two species. This finding is not entirely consistent with previous work on other species. Schieck and Millar (1985) stated that small intestine lengths did not accurately reflect the amount of fibre in the diet of the 35 small mammal species they examined. Similarly, Milton (1981) and Hladik (1967) showed that small intestinal surface areas of the sympatric primates *Alouatta palliata* and *Ateles geoffroyi* (even with their extremely different diets) were approximately equivalent. Jones (1970) also found that relative lengths of the small intestine were fairly constant among the eight African

cercopithecids he studied. However, CHIVERS and HLADIK (1980) showed, by regressing surface area of small intestine against body size, that absorptive surface area increases proportionately with metabolic body mass. The generally larger areas of small intestine in samangos might therefore simply be a factor of their larger size. Also, the consistently larger (relative) surface area in adult females (than males) might be related to the greater energy demands of the female during pregnancy and lactation, which are known to cause an increase in both small intestinal length and water content (CRIPPS and WILLIAMS 1975; GROSS et al. 1985).

The caecum and colon of samangos were highly significantly more voluminous than those of vervets. This finding of greater caecal and colonic lengths and volumes in the more herbivorous species is well supported by previous studies. SCHIECK and MILLAR (1985) reported that colon lengths and weights represented diet types well, with herbivores having relatively larger large intestines than granivores and omnivores. JONES (1970) found that in eight cercopithecids the more folivorous species possessed relatively greater colon lengths, and in some cases greater caecum length. Similarly, MILTON (1981) showed that the folivorous *Alouatta palliata* possessed a longer colon (double the surface area) than the frugivorous *Ateles geoffroyi.*

The caecum of herbivores is also generally larger than that of granivores or omnivores (SCHIECK and MILLAR 1985), and functions in the microbial conversion of fibrous material into compounds that can be absorbed by the colon (SHARKEY 1971). Evidence for the importance of the caecum of the samango in fermentation has already been presented (BRUORTON and PERRIN 1988). A further study has also shown high concentrations of organic acids, as well as numerous bacteria, within the caecum and colon of both samangos and vervets.

It might be expected that the larger volumes of caecum and colon in the more folivorous samangos confers some selective advantage over vervets with respect to microbial digestion of leaves and other fibrous material. This would occur if the greater volumes were found to be important in food retention (or decelerating the passage rate of fibrous material), or if different species of fibre-digesting bacteria were present in one of the species. However, CLEMENS and MALOIY (1981) and CLEMENS and PHILLIPS (1980) have shown that passage rates of food in vervets and in Sykes monkey *C. mitis kolbi* are extremely similar, with vervets retaining some particulate markers for longer time periods than did Sykes. They also suggest that food retention is not necessarily an important factor for the accumulation of organic acids, as high concentrations were observed in the colon of the bushbaby *Galago crassicaudatus* (CLEMENS and MALOIY 1981), which is smooth and non-complex and permits rapid passage of digesta. It is also suggested that herbivorous primates do not necessarily hold a fermentative advantage over omnivorous primates (CLEMENS and PHILLIPS 1980), and that GIT structure does not appear to influence the concentrations of organic acids found in the mammalian hindgut.

Any advantages conferred by larger hindgut volumes are probably related to fermentation capacity in the two species. The larger the volume, the greater the amount of organic acids which may be produced by the microbial populations. Thus, even though the concentrations of organic acids in the hindgut of the two species are similar, the larger caecum and colon of the samango allows for greater production of these important microbial degradation compounds. Volatile fatty acids are rapidly absorbed by the large-intestinal mucosa of a wide range of mammalian species, usually at a rate similar to that determined for rumen epithelium (RERAT 1978; STEVENS et al. 1980). However, the quantity of organic acids absorbed by the large intestine of a given species depends primarily upon the surface area available (STEVENS et al. 1980). With the high component of leaf material in their diets, the extensive hindgut regions of samangos are, therefore, not only important in allowing a greater production of organic acids, but also for the greater absorption and assimilation of these important fermentation end-products.

Acknowledgements

We would like to thank the Natal Parks Board for issuing us with permits to collect 10 samangos. MRB thanks the Foundation for Research Development (C.S.I.R.) of South Africa for a bursary during the course of his study, and both authors thank the University Research Committee of the University of Natal for funds granted during the course of the study.

Zusammenfassung

Vergleichend-morphometrische Untersuchungen am Verdauungskanal von Grünaffen (Cercopithecus aethiops) und Diademaffen (C. mitis)

Vergleichend-morphometrische Untersuchungen am Verdauungskanal von Grünaffen und Diademaffen zeigten, daß Diademaffen wesentlich größere Raumanteile im hinteren Darm (Caecum und Colon) besitzen. Die Hauptabsorptionsoberflächen des Verdauungskanals (das Ileum) zeigte bei Diademaffen ebenfalls größere Ausdehnung als bei Grünaffen. Diademaffen fressen grundsätzlich mehr faseriges Laubmaterial als Grünaffen. Die Bedeutung der größeren Darmräume wird im Hinblick auf den Gärungsprozeß, der zu Aufbereitung und Verdauung dieses Laubbestandteils nötig ist, diskutiert.

References

Bruorton, M. R. (1989): A comparative morphological and physiological examination of the gastrointestinal tracts of vervet and samango monkeys. M. Sc. Diss., Univ. Natal, Pietermaritzburg, South Africa.

Bruorton, M. R.; Perrin, M. R. (1988): The anatomy of the stomach and caecum of the Samango monkey, *Cercopithecus mitis erythrarchus* Peters, 1852. Z. Säugetierkunde **53**, 210–224.

Chivers, D. M.; Hladik, C. M. (1980): Morphology of the gastrointestinal tract in primates: comparisons with other mammals in relation to diet. J. Morphol. **116**, 337–386.

Clemens, E. T.; Phillips, B. (1980): Organic acid production and digesta movement in the gastrointestinal tract of the baboon and sykes monkey. Comp. Biochem. Physiol. **66**, 529–532.

Clemens, E. T.; Maloiy, G. M. O. (1981): Organic acid concentrations and digesta movement in the gastrointestinal tract of the bushbaby *(Galago crassicaudatus)* and vervet monkey *(Cercopithecus pygerythrus)*. J. Zool., Lond. **193**, 487–497.

Cords, M. (1987): Mixed-species associations of *Cercopithecus* monkeys in the Kakamega forest, Kenya. Berkeley: University of California Press.

Cripps, A. W.; Williams, V. J. (1975): The effect of pregnancy and lactation on food intake, gastrointestinal anatomy and the absorptive capacity of the small intestine in the albino rat. Br. J. Nutr. **33**, 17–32.

Dunbar, R. I. M.; Dunbar, E. P. (1974): Ecological relations and niche separation between sympatric terrestrial primates in Ethiopia. Folia. primatol. **21**, 36–61.

Gross, J. E.; Wang, Z.; Wunder, B. A. (1985): Effects of food quality and energy needs: changes in gut morphology and capacity of *Microtus ochrogaster*. J. Mammalogy **66**, 661–667.

Hill, W. C. O. (1958): Pharynx, oesophagus, stomach, small intestine and large intestine. Form and position. Primatol. **3**, 139–207.

— (1966): Primates. Comparative anatomy and taxonomy. VI. Catarrhini, Cercopithecoidea, Cercopithecinae. New York: Interscience Publ.

Hladik, C. M. (1967): Surface relative du tractus digestif de quelques primates, morphologie des villosites intestinales et correlations avec le regime alimentaire. Mammalia **31**, 120–147.

Johnson, J. L.; McBee, R. H. (1967): The porcupine caecal fermentation. J. Nutrition **91**, 540–546.

Jones, C. (1970): Stomach contents and gastrointestinal relationships of monkeys collected at Rio Muni, West Africa. Mammalia **34**, 107–117.

Kavanagh, M. (1978): The diet and feeding behaviour of *Cercopithecus aethiops tantalus*. Folia primatol. **30**, 30–63.

Langer, P. (1988): The mammalian herbivore stomach. Comparative anatomy, function and evolution. Stuttgart, New York: Gustav Fischer Verlag.

Lawes, M. J. (1990): Socio-ecology of the samango monkey and conservation in Natal. Ph. D. Diss., Univ. Natal, Pietermaritzburg, South Africa.

Milton, K. (1981): Food choice and digestive strategies of two sympatric primate species. Amer. Nat. **117**, 496–505.

Perrin, M. R. (1987): Effect of diet on the gastric papillae and microflora of the rodents *Mystromys albicaudatus* and *Cricetomys gambianus*. S. Afr. J. Zool. **22**, 67–76.

Poksey, K. S.; Schneeman, B. O. (1983): Pancreatic and intestinal response to dietary guar gum in rats. J. Nutr. **113**, 1544–1549.

Rerat, A. (1978): Digestion and absorption of carbohydrates and nitrogenous matters in the hindgut of the omnivorous nonruminant animal. J. Anim. Sci. **46**, 1808–1837.

Rudran, R. (1978): Intergroup dietary differences and folivorous tendencies of two groups of blue monkeys, *Cercopithecus mitis*. In: The ecology of arboreal folivores. Ed. by G. G. Montgomery. Washington D. C.: Smithsonian Inst. Press.

Schieck, J. O.; Millar, J. S. (1985): Alimentary tract measurements as indicators of diets of small mammals. Mammalia **49**, 93–104.

Sharkey, M. J. (1971): Some aspects of coprophagy in rabbits and guinea pigs fed fresh lucerne. Mammalia **35**, 162–168.

Stevens, C. E.; Argenzio, R. A.; Clemens, E. T. (1980): Microbial digestion: rumen versus large intestine. In: Digestive physiology and metabolism in ruminants. Ed. by. Y. Ruckebusch and P. Thivend. Westport, Connecticut: Avi Publishing Comp.

Watson, L. H. (1985): The feeding ecology of chacma baboons and vervet monkeys in the Hluhluwe-Umfolozi Reserve. M. Sc. Diss., Univ. Natal, Pietermaritzburg, South Africa.

Zar, J. H. (1974): Biostatistical analysis. London: Prentice-Hall International.

Authors' address: Michael R. Bruorton and Prof. Dr. Michael R. Perrin (for correspondence), Department of Zoology and Entomology, University of Natal, P. O. Box 375, Pietermaritzburg 3200, Natal, South Africa