

## 9.—The development of the cheek-teeth in *Antechinus flavipes* (Marsupialia, Dasyuridae)

by Michael Archer<sup>1</sup>

Manuscript received 20 March, 1973; accepted 19 March, 1974.

### Abstract

The ontogenetic development of the cheek-teeth in a developmental series of 14 pouched young of *A. flavipes* is described. There were found to be eight post-canine tooth families each of which produces only one tooth, or generation: P1, P3, P4, dP4, M1, M2, M3, M4. The canine family has two generations. The development of the upper and lower laminae differ in the posterior region probably because of the crowding effect in the mandible caused by the ascending ramus. The time of initiation of all teeth is consistent with an interpretation described by Woerdman (1921) as *Zahnreihen*. In *A. flavipes* there appear to be two *Zahnreihen* along the length of the cheek-tooth row. One is initiated at the C position and the other at the dP4 position. The molariform cheek-tooth series, the dP4-M4, represent one series of related teeth, and the C-P4 represent a second set of related cheek-teeth. The traditional definitions of premolars and molars do not apply to cheek-teeth of *A. flavipes* and if the situation that exists in this species is found to be more general among the marsupials, a more appropriate series of definitions and nomenclature may be required to differentiate the cheek-teeth.

### Introduction

Numerous attempts have been made by research workers to establish a basis for identifying homologous teeth in metatherians (marsupials) and eutherians. The most commonly used basis is the phenomenon of tooth replacement. Owen (1840-5) established the basic principle that premolars were post-canine teeth which had milk predecessors. Molars were post-premolar teeth which had no milk predecessors. Accordingly, eutherians are considered to have four premolars and three molars. Metatherians, which presumably have a common ancestry with eutherians, have three premolars and four molars. Consequently it appears that metatherians have lost one premolar and gained or retained an additional molar. An alternative is that the first molar of metatherians is actually a molariform premolar. Differences in opinion about which premolar has been lost (if in fact any have been lost) have produced conflicting systems of dental terminology.

Embryological investigations have often tended only to confuse the issue. As a result of some of the earlier embryological studies, the question of the homology of the whole tooth row was raised and has been the cause of further conflicting terminologies. Most embryological investigations were, however, carried out on material inadequate to clarify the questions of premolar

and molar homology. Either the studies have been based on too few or too late developmental stages (e.g. Wilson & Hill 1897, Fosse & Risnes 1972a and b), or upon excellent material of species which have incomplete series of teeth due to phylogenetic reduction (e.g. the macropodids as studied by Berkovitz 1966, and Kirkpatrick 1969, or phalangerids studied by Berkovitz 1968).

The work reported here was based on a good series of pouch young of *Antechinus flavipes* whose adult cheek-tooth dentition contains the maximum number of teeth known in any metatherian except *Myrmecobius* which appears to develop supernumary teeth of very uncertain homology; some Cretaceous *Didelphodon*, Clemens 1966, which may have had four premolars; and possibly *Garzonia*, a specimen noted by Sinclair (1906) having nine antemolar teeth of uncertain homology.

The teeth of vertebrates are basically ectodermal structures which develop from oral epithelial tissue. In reptiles (Edmund 1960), the oral epithelium invaginates as a band (the dental lamina) into the matrix of the upper and lower jaws. The free edge of the invaginating band is proliferative and sequentially along its length produces swellings which are identified as tooth buds. As these tooth buds organize and develop the tissues which will eventually produce a functional tooth, they appear to move along the buccal side of the dental lamina, in a vertical direction, towards the oral epithelium. This relative movement of the bud and the free edge of the dental lamina is responsible for the re-appearance of the free edge lingual to the established tooth bud. Subsequently, a second swelling may occur on the free edge of the dental lamina in the same position as the first. Such a vertical sequence of one or more tooth buds is referred to as a tooth family. Each bud is referred to as a tooth generation. There may be many tooth families along the dental lamina and a variable number of generations within each. The situation in mammals is basically the same (Ziegler 1972) except that the invaginated dental lamina is less sheet-like in structure, and as a result the terminal swellings occur nearer to the oral epithelium.

The work presented here is an attempt to determine the number of post-canine tooth families, and generations within those families, in the dasyurid marsupial *Antechinus flavipes*. This information is used to clarify the homologies of the cheek-teeth of metatherians.

<sup>1</sup> Western Australian Museum, Francis Street, Perth, Western Australia 6000. Present address: Queensland Museum, Fortitude Valley, Queensland 4006.



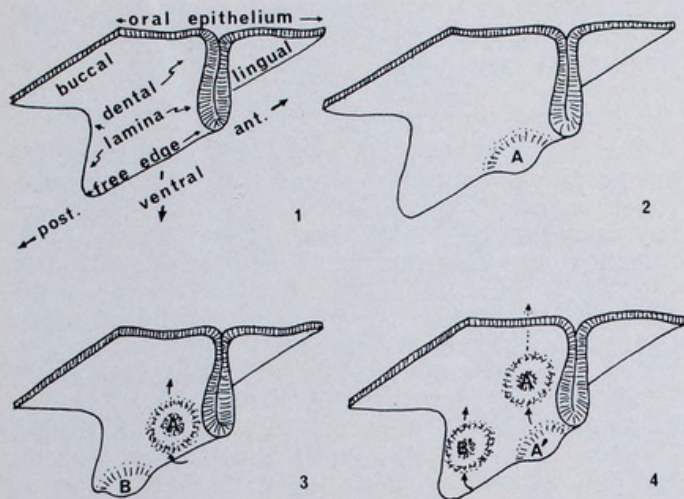


Figure 1.—A schematic and simplified portrayal of the relationship of tooth generations and families to a transected part of the lower dental lamina (modified after Edmund 1960).

1. The dental lamina as an ingrowth of oral epithelium.
2. A terminal swelling (A) of the dental lamina indicating the initiation of a tooth.
3. The tooth (A) appears to rise on the buccal side of the dental lamina and the free edge becomes visible again. A second tooth (B) is initiated posterior to the first (A), again as a terminal swelling of the free edge of the dental lamina.
4. The first tooth (A) initiated is considerably enlarged and now lies just beneath the oral epithelium through which it will eventually erupt. A second swelling (A') of the free edge of the dental lamina beneath the first tooth (A) establishes a second generation in vertical tooth family A.

### Material and methods

Three female *Antechinus flavipes leucogaster* from the Wongong River watershed near Byford, W.A., gave birth in captivity during 1969 and 1970. In 1969 eight pouch young were removed from two females at intervals of 4-11 days. One of these young duplicated a developmental stage. In addition two young were preserved at 83 and 105 days from birth. In 1970, six young were removed at intervals of 5-10 days. The sixteen animals removed represented fifteen developmental stages. All of the young were fixed in neutral formalin. With the exception of the 83 and 105 day animals and the single animal which duplicated a developmental stage, the fixed young were decapitated and the heads decalcified in 5.5% ethylene diamine tetra-acetic acid (E.D.T.A.) solution, doubly-embedded using Peterfi's method, and sectioned transversely at 8U. Sections were stained in haematoxylin and eosin. The animal which duplicated a developmental stage was decapitated. The head was cut sagittally: one half was macerated in KOH and stained in alizarin red S solution (as described in Dawson 1926) and cleared in glycerine; the other half was sectioned sagittally and processed as described above for the transverse sections. Two heads of pouch young of unknown age were sectioned transversely and allocated to the series, on the basis of structural development, to the 60+ day developmental stage.

### Results

The basic observations of initiation, re-establishment of the free-edge of the dental lamina, calcification and eruption are presented in Tables 1-2.

#### The families of cheek-teeth and their generations

A tooth bud was considered to be initiated when the free edge of the dental lamina possessed a terminal swelling bounded both anteriorly and posteriorly by relatively unswollen free edge. In addition each tooth bud could be

Table 1

The development of the cheek-tooth families in the lower jaw.\*

Stages	C <sub>1</sub>	dC <sub>1</sub>	P <sub>1</sub>	P <sub>3</sub>	P <sub>4</sub>	dP <sub>4</sub>	M <sub>1</sub>	M <sub>2</sub>	M <sub>3</sub>	M <sub>4</sub>
4 Day						S				
10 Day										
12 Day	S	FE					S			
15 Day			S			FE				
" 22 " Day								S		
21 Day										
28 Day	FE	END	FE			C	FE	C		S
32 Day	C		C	S				FE		
36 Day								C		
40 Day				FE	S				FE	
44 Day									C	S
51 Day										
59 Day										FE?
60+ Day			EG			EG				
83 Day	ED		ED	ED		ED	ED	ED	ED	
105 Day					C					ED

\* The stages are approximations based on time from date of birth (with a probable error of less than two days). The animal representing the 22 Day Stage was found to be slightly younger than the 21 Day Stage animal on the basis of relative development. The 60+ Day Stage animal is of unknown age but on the basis of structural development represents a stage between the 59 Day Stage and the 83 Day Stage. The 83 and 105 Day Stage animals were not sectioned. S = initiation; FE = free edge of the dental lamina on the lingual side of the tooth; C = calcification; EG = erupting, i.e. just having pierced the oral epithelium; ED = erupted.



**Table 2**

*The development of the cheek-tooth families in the upper jaw.\**

Stages	C <sup>1</sup>	dC <sup>1</sup>	P <sup>1</sup>	P <sup>3</sup>	P <sup>4</sup>	dP <sup>4</sup>	M <sup>1</sup>	M <sup>2</sup>	M <sup>3</sup>	M <sup>4</sup>
4 Day		S								
10 Day	S					S				
12 Day										
15 Day							S			
" 22 " Day						FE				
21 Day			S			C	FE			
28 Day	FE C							S		
32 Day			FE	S			C			
36 Day			C					FE	S	
40 Day				C	S					
44 Day		END		FE				C		
51 Day										
59 Day									FE	
60+ Day			EG						C	S
83 Day	ED		ED	ED		ED	ED	ED	EG?	
105 Day					C				ED	C

\* The stages and abbreviations are the same as those given in Table 1.

identified with its homologue in each consecutive developmental stage either to the stage of eruption, calcification, or in the case of the deciduous canine, resorption. The sectioned stages did not provide the later developmental stages of the P<sup>4</sup> or M<sup>4</sup> because of the late initiation of these teeth.

Generally less than five developmental stages after the initiation of a tooth was observed, the terminal free edge of the dental lamina was again visible at the tooth position, lingual to the tooth bud. The tooth bud thus appeared to have risen up the buccal side of the dental lamina relative to the free edge.

With the exception of the deciduous canine, no second generation swellings were observed at established family positions. Therefore, each post-canine tooth family consisted of only one generation of teeth. Although incisor development is not considered here, it should be pointed out that deciduous incisors were present in

association with each incisor position. These generally reached the stage of calcification and were then resorbed.

#### *The identification of cheek-tooth families*

The identification of each tooth family that appeared in sequence along the entire lamina from anterior to posterior end was based on the terminology of Thomas (1887). They are in anterior to posterior order: C; P<sup>1</sup>; P<sup>3</sup>; P<sup>4</sup>; dP<sup>4</sup>; M<sup>1</sup>; M<sup>2</sup>; M<sup>3</sup>; M<sup>4</sup>. Application of these terms to the teeth in question does not mean that I imply any successional relationship between any of the teeth or believe a P<sup>2</sup> family is lost in the dentition of *Antechinus flavipes*. Thomas's (1887) nomenclature is used simply because it is familiar and widely accepted in connection with Australian metatherians.

#### *The sequence of the establishment of cheek-tooth families*

In the earliest stage (4 days post-birth) two family positions are established: the C and the dP<sup>4</sup>. In the upper jaw (the anterior end of the dental lamina of the lower jaw was damaged in the youngest stages) the C was a discrete terminal swelling. The first tooth bud is interpreted to represent a milk canine (dC) as, in the next developmental stage, there is a swollen free edge lingual to the dC which is the homologue of the erupting C. DP<sup>4</sup> was also a terminal swelling.

Between these two family positions three additional positions were seen to be established in later stages in sequential order as summarized in Tables 1-2: the P<sup>1</sup>, P<sup>3</sup>, and P<sup>4</sup> positions. More or less synchronously with the appearance of the ante-molar positions, four tooth family positions were seen to be established posterior to the dP<sup>4</sup>; M<sup>1</sup>, M<sup>2</sup>, M<sup>3</sup> and M<sup>4</sup>.

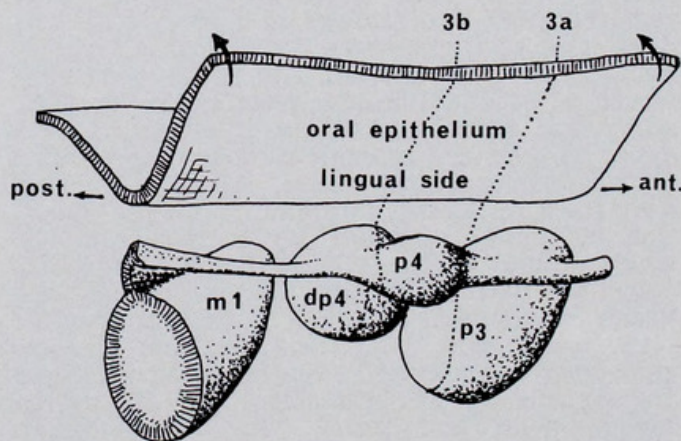


Figure 2.—A schematic portrayal of the region of the lower dental lamina at the 40 Day Stage. The P<sup>4</sup> occurs as a swelling of the free end of the dental lamina which is by this stage suspended between the lingual walls of the P<sup>3</sup> and dP<sup>4</sup>. The mass of the swelling is actually slightly closer to the dP<sup>4</sup> than it is to the P<sup>3</sup>. The lingual side of the oral epithelium has been slightly displaced dorsally. Note that the dental lamina has lost contact with the oral epithelium in this relatively late stage (compare with Fig. 6 showing the condition in the 28 Day Stage). Dotted lines 3a and 3b indicate approximate positions of transverse section photographs shown in Fig. 3.



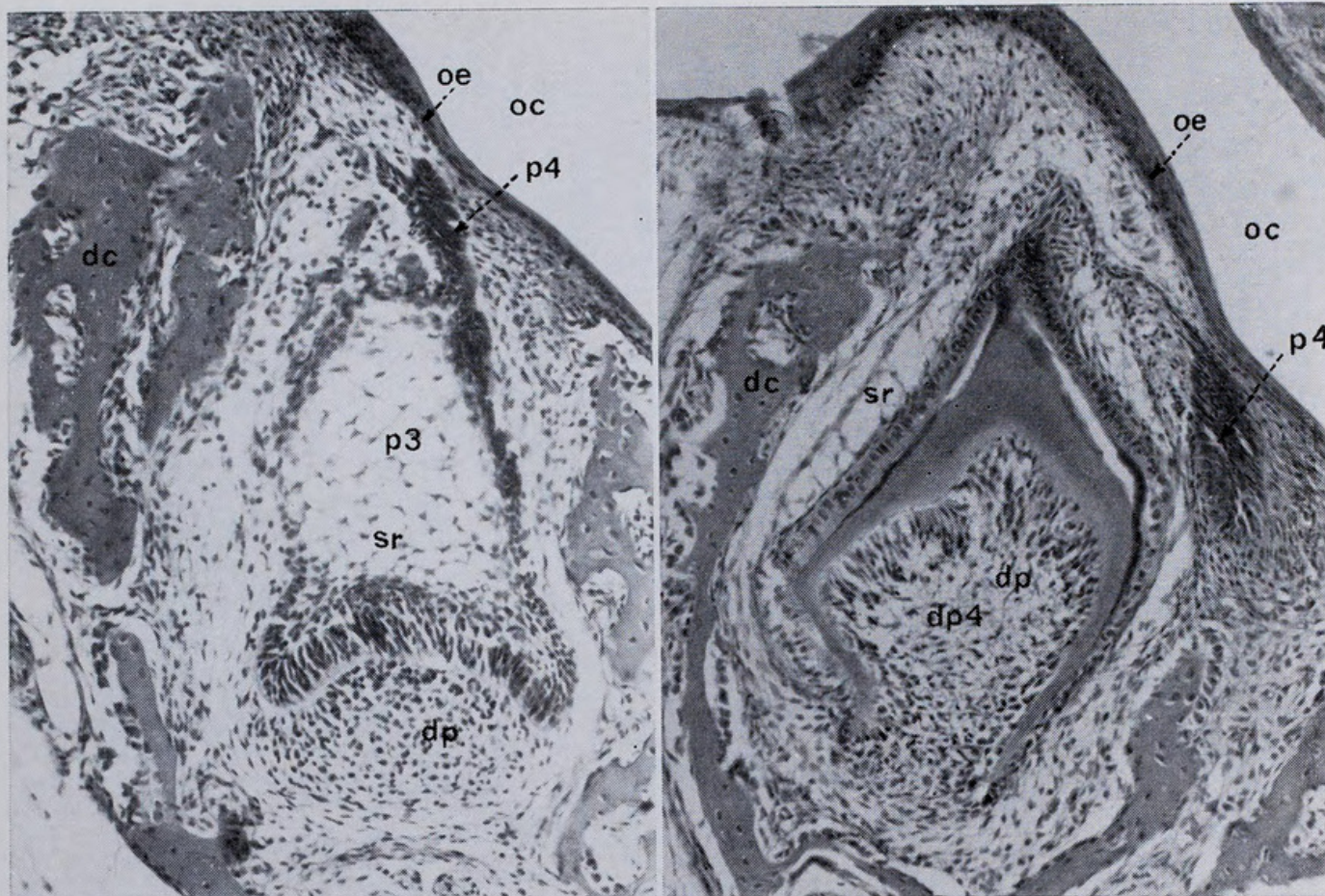


Figure 3.—Photographs of transverse sections of the 40 Day Stage dental lamina. (a) Section through the P<sub>3</sub> near its posterior end where the dental lamina representing the anterior end of the P<sub>4</sub> adheres to the lingual side. (b) Section through the dP<sub>4</sub> where the P<sub>4</sub> swelling is connected to the dP<sub>4</sub> by a thin band of dental lamina. Abbreviations: oe, oral epithelium; oc, oral cavity; dp, dental papilla; sr, stellate reticulum; dc, cartilage of the dentary bone; fe, free edge of the dental lamina.

*The form of the dental lamina and its free edge with particular reference to the establishment of cheek-tooth positions*

In the earliest stage examined the dental lamina posterior to the C position was of uniform depth, continuous, and in contact with the oral epithelium. In subsequent stages, when tooth initiation had occurred, the dental lamina and/or its free edge associated with the developed tooth appeared to be more distant from the oral epithelium than was the free edge of the inter-tooth dental lamina. In addition, as tooth development occurred there was a tendency to lose contact with the oral epithelium in the region of tooth development. This produced the appearance, particularly in the lower jaw in later stages, of the dental lamina existing as a ribbon stretched or hung between the lingual walls of the developed tooth buds. When the P<sub>4</sub> had initiated, it was flanked anteriorly and posteriorly by two well-developed tooth buds: the dP<sub>4</sub> and the P<sub>3</sub>. In the last sectioned developmental stage (60+ Day Stage), the dental lamina connecting P<sub>4</sub> to the surrounding teeth had degenerated, leaving the P<sub>4</sub>, which was in that stage still an enlarged swelling of laminar tissue, isolated in the matrix of the lower jaw lingual and anterior to the well-developed dP<sub>4</sub>.

In the earliest stages examined, the dental lamina did not extend posterior to the dP<sub>4</sub> position. The dP<sub>4</sub> itself appears to represent a terminal swelling at the posterior end of the dental lamina's free edge. One stage later the dental lamina is seen to extend posterior to the dP<sub>4</sub> and to be swollen slightly to form the M<sub>1</sub>.

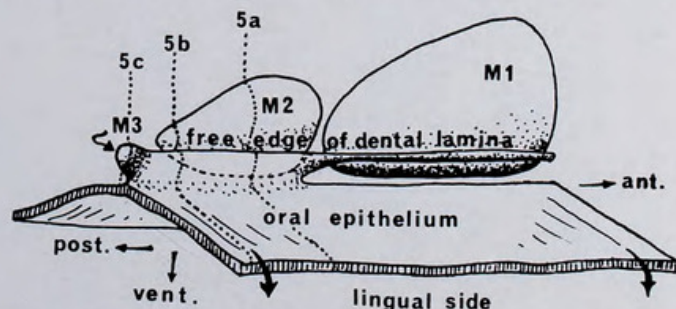


Figure 4.—Schematic portrayal of the dental lamina and associated structures at the 44 Day Stage to demonstrate the upper molar relationships. The lingual side of the oral epithelium has been slightly depressed ventrally to expose the dental lamina. The dental lamina is in contact with the oral epithelium at its posterior edge. The terminal swelling which represents M<sub>3</sub> is continuous with the free edge of the dental lamina lingual to the M<sub>2</sub>. In a later stage (the 59 Day Stage) the free edge of the dental lamina is again visible at the M<sub>3</sub> position lingual to the M<sub>3</sub>. Dotted lines 5a, 5b, and 5c indicate approximate positions of transverse section photographs shown in Fig. 5.



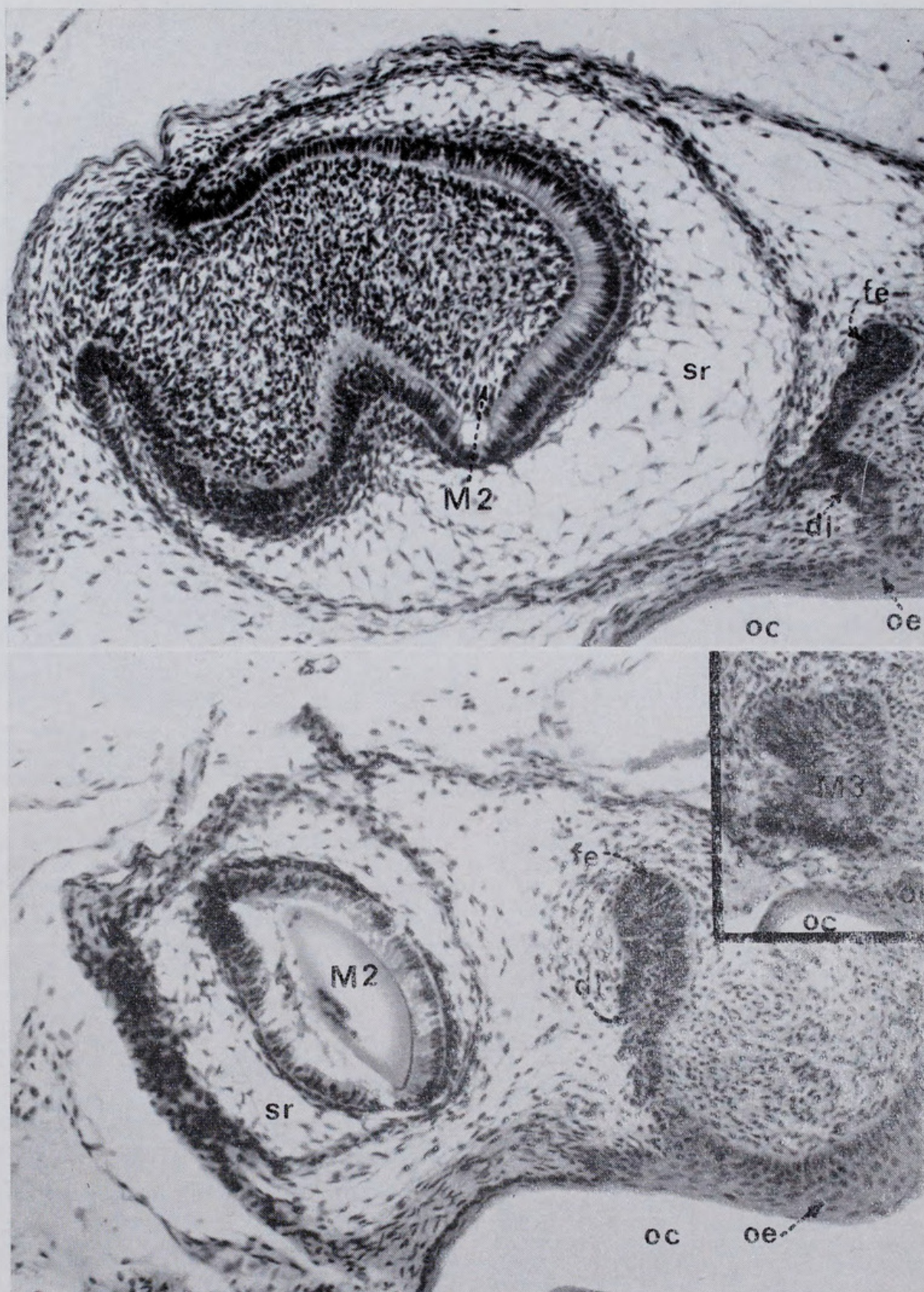


Figure 5.—Photographs of transverse sections of the 44 Day Stage dental lamina. (a) Section through the M<sup>2</sup> showing its connection with the dental lamina which is in turn connected to the oral epithelium. The free edge of the dental lamina, extending dorsally from the dental lamina on the lingual side of the M<sup>3</sup>, is sectioned anterior to the point at which it swells to form the M<sup>3</sup> swelling. (b) Section through the posterior end of the M<sup>2</sup> and the free edge of the dental lamina which is attached to the oral epithelium. The free edge is thicker than in (a) above but is still anterior to the position of the M<sup>3</sup> swelling. (c) Section through the posterior end of the M<sup>3</sup> swelling. Abbreviations as in Fig. 3.



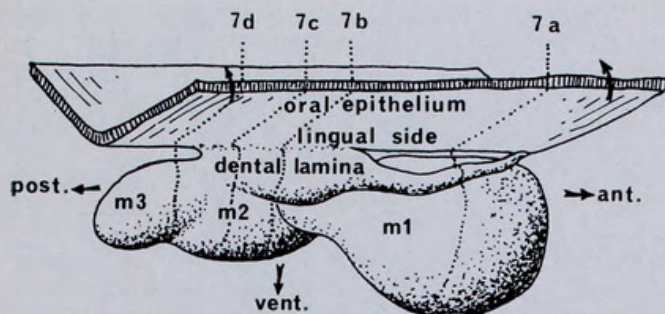


Figure 6.—Schematic portrayal of the lower dental lamina and associated structures at the 28 Day Stage. The lingual side of the oral epithelium has been lifted dorsally to expose the dental lamina. The free edge of the dental lamina has been re-established lingual to the  $M_1$  and in the anterior region of the  $M_2$ . It has not yet been re-established along the posterior edge of  $M_2$ . The posterior region of the dental lamina is not in vertical contact with the oral epithelium and is poorly differentiated from the posterior region of the  $M_2$ . The part that is differentiated lingually and extended terminally represents the initiating  $M_3$ . Dotted lines 7a, 7b, 7c, and 7d indicate approximate positions of transverse section photographs shown in Fig. 7.

At that stage the free edge of the dental lamina is not visible on the lingual side of the dP4. It was, however, visible just prior to the establishment of  $M_2$ .

In the upper jaw the free terminal edge of the dental lamina appears to be more or less vertical in each stage as it is seen to extend farther posteriorly. It maintains continuity with the oral epithelium in the region of posterior growth but further anteriorly, in regions where teeth have been established several stages earlier, the connection with the oral epithelium breaks down. In the upper jaw posterior to the  $M^1$  and in stages after the  $M^1$  is established, the free edge of the dental lamina is seen to be established on the lingual side of the tooth bud prior to, or simultaneously with, the establishment of the next molar position. In the lower jaw the dental lamina is seen to extend posteriorly, in stages post-dating the establishment of the  $M_1$ , such that the ventral free end extends farther posteriorly than the dorsal fixed end in contact with the oral epithelium. This difference in position appears to suggest that the ventral free end extends posteriorly at a more rapid rate than does the dorsal fixed end. As in the case of the upper lamina, in later stages in regions where teeth have been established in several previous stages, the dental lamina is seen to have lost its contact with the oral epithelium. In contrast, however, with the upper lamina, the free edge of the dental lamina of the lower jaw lingual to each tooth is not visible prior to, or simultaneously with, the establishment of the next molar. It does not normally (except in the case of  $M_3$ ) appear until at least one stage after the initiation of the next posterior molar position.

### Discussion

#### *Tooth replacement and the Zahnreihe theory*

It is clear that in *Antechinus flavipes* teeth established posterior to the C position are separate tooth families and each has only one

generation. There are therefore no true successional post-canine teeth in the sense of milk and permanent teeth of succeeding generations such as are believed to occur in most eutherians. This supports the observations of Woodward (1893), Engelhardt (1933), Dressel (1931), Litlich (1933), and Berkovitz (1966 and 1967) that the P4 develops from the dental lamina between the P3 and dP4 positions and is not a successor to either. It does not support the contention of Kirkpatrick (1969) that P4 is a successional tooth in the same family as the P3, nor does it support the contention of Wilson & Hill (1897) and other earlier workers that P4 was the successor to dP4.

Berkovitz (1972) describes tooth replacement in the Guinea Pig (*Cavia coby*). He notes that in the upper dentition the so-called replacement premolar develops from dental lamina lying anterior to the so-called deciduous premolar. This is a situation comparable with the condition in *Antechinus* in that the replacing tooth does not develop in a position clearly lingual to the deciduous tooth. However, in the lower dentition of the Guinea Pig, the replacement tooth develops as a lingual downgrowth of dental lamina associated with the posterior half of the enamel organ of the deciduous tooth. Unfortunately, the actual homology of these teeth in Guinea Pigs is uncertain (Berkovitz 1972), and all of the teeth, including the molars may belong to one generation. Ziegler (1972) describes tooth replacement in the eutherian Mole *Scapanus latimanus* and demonstrates that replacement teeth develop from the free edge of the dental lamina that develops from the lingual edge of the deciduous tooth germ. This manner of tooth replacement is unlike that seen in the *Antechinus* dP4 and P4 in the present study, but is comparable with the situation observed here for the deciduous and replacement incisors and canines.

On the basis of the evidence presented in this study, the manner in which the upper  $M_2$ -4 develop in *A. flavipes* is not identical with the manner in which the lower  $M_2$ -4 develop; this difference in ontogenetic behaviour of upper and lower dentitions parallels the condition observed in *Cavia* by Berkovitz (1972, see above). In the posterior region of the upper jaw the dental lamina is firmly in contact with the oral epithelium as new molar positions are initiated. By the time these initiations occur, posterior to  $M^1$ , the free edge of the dental lamina is established on the lingual side of the previous molar. Consequently it is clear that each molar position is a separate family position which subsequently supports or lies buccal to a lingual free edge of dental lamina. This re-establishment of the free edge of the dental lamina appears to be either a passive phenomenon relating to the movement orally of the established tooth germ or else a positive development of the dental lamina as a means of maintaining the developmental potential continuously along the dental lamina. It does not appear to be a necessary prerequisite to the establishment of posterior tooth positions (as Kirkpatrick, 1969,



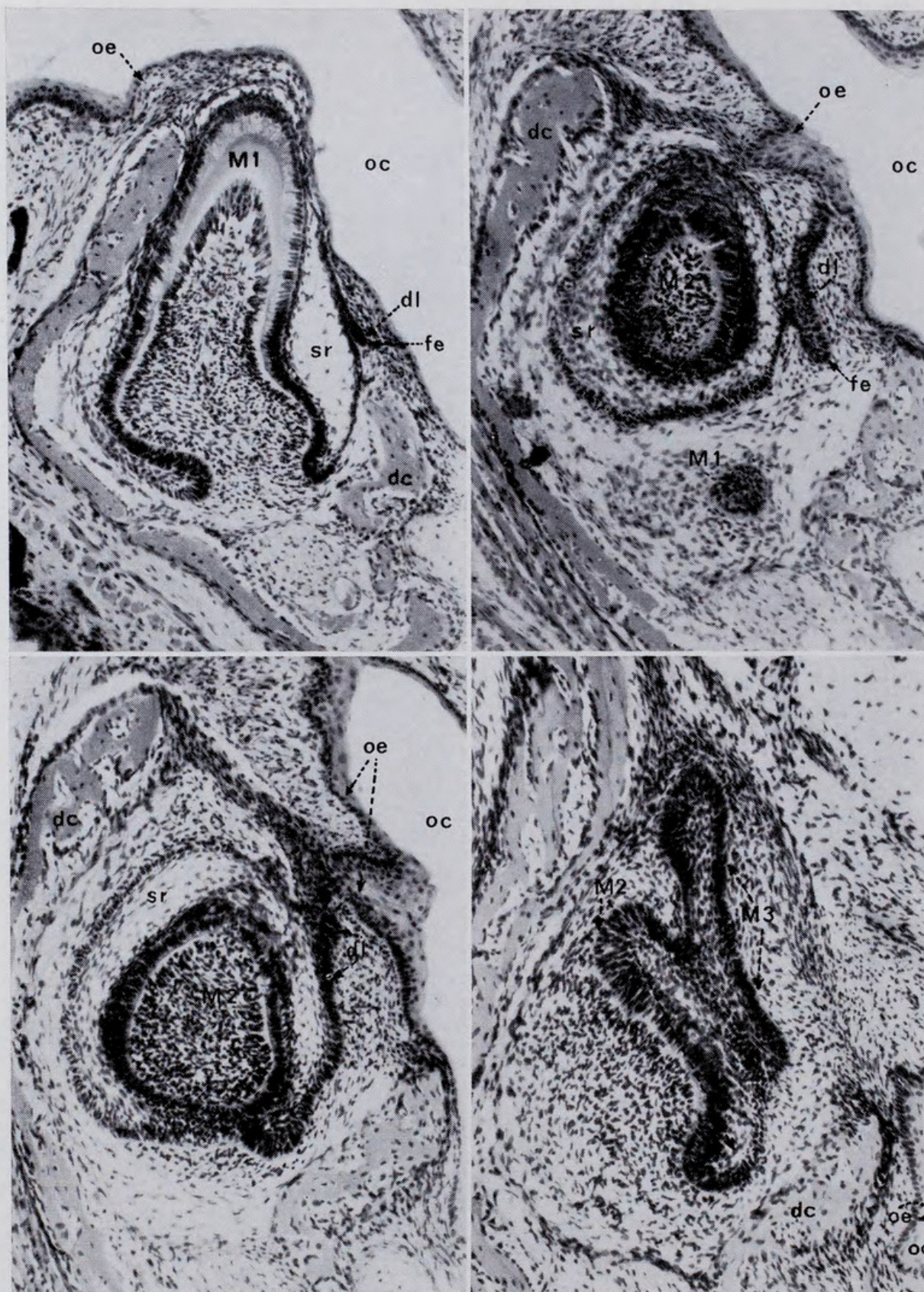


Figure 7.—Photographs of transverse sections of the 28 Day Stage dental lamina. (a) Section through the  $M_1$  showing a small remnant of dental lamina adhering to the lingual side of  $M_1$  and not connected to the oral epithelium at this point. (b) Section through  $M_1$  and  $M_2$  showing contact between  $M_2$  and the dental lamina and the latter with the oral epithelium. Note the thickened epithelial cells (which is proliferative dental lamina) on the lingual side of the  $M_2$  which marks the anterior extremity of the  $M_3$  swelling. (c) Section through the  $M_2$  and  $M_3$  in the region where they are side by side. The  $M_3$  is developed as an overgrowth of dental lamina passing postero-lingual to the  $M_2$ . At this point neither the  $M_2$  nor the  $M_3$  are in contact with the oral epithelium. Abbreviations as in Fig. 3.



has implied by suggesting that dP4 and M1-4 are successional replacement teeth of one family) as is clearly demonstrated by its retarded re-establishment of the lower dental lamina. This delayed re-establishment of the free edge, as well as the apparent lag in the posterior extension of the junction between the fixed end of the dental lamina and the oral epithelium, constitute the major differences between the development of the lower and upper dental lamina in the molar region. The difference may be caused by the presence of an ascending ramus in the lower jaw. In all later stages, the posterior part of the dental lamina appears to be not only crowded but almost looped. The molars, as they develop, tend to overlap. This could account for the delay in the establishment of a vertical relationship between a lower molar and the oral epithelium which would not or could not occur until such time as the mandible has sufficiently lengthened to permit or facilitate a vertical connection. In the upper jaw, it is clear that bony processes provide no obstacles to development. The developing molars are seen to extend out beneath the orbit where they may be, so to speak, waiting for the maxilla to catch up and provide bony crypts.

Churchill (1935) describes molar formation and its relationship to the dental lamina and oral epithelium in *Homo sapiens*. Except for a slightly more advanced rate of re-establishment of the free edge of the dental lamina, it is a situation remarkably similar to that visualized in this study for the posterior region of the lower dental lamina in *Antechinus flavipes*. He even demonstrates the same difference in the rate of posterior development between the proliferative terminal free edge and the fixed edge of the dental lamina.

The order of initiation of the cheek-teeth in *A. flavipes* clearly suggests that there are in fact two distinct series of temporarily related teeth which are also, in many dasyurids (e.g. species of *Sminthopsis*), distinct morphological series. The molariform series is the dP4-M4. The two series resemble the *Zahnreihen* postulated by Woerdman (1921). Edmond (1960) developed the theory of *Zahnreihen* and suggested that some form of pulse passed along the free edge of the dental lamina initiating, as it passes, tooth buds at predetermined tooth family positions. To explain the unique partial-replacement condition seen in so many eutherians, he visualized first one pulse passing continuously along the free edge, producing all of the milk teeth and permanent molars. Then a second pulse would sweep along the free edge but only for about half the length of the lamina's free edge. The pulse would then stop. This would result in the initiation of a series of second generation teeth developing beneath the anterior teeth, and these would of course represent the permanent replacement teeth. In similar terms, the situation in *Antechinus flavipes* may be that two cheek-tooth centres for the initiation of *Zahnreihen* exist (i.e. C and dP4) and that the two rows of teeth initiated by passing waves

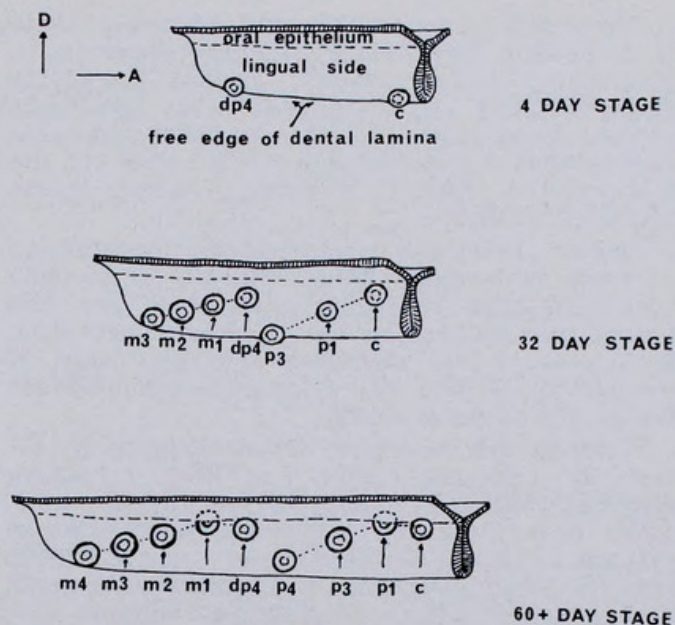


Figure 8.—A schematic portrayal of *Zahnreihen* as evidenced in the developing lower cheek tooth row of *Antechinus flavipes*. Two separate centres for wave initiation are postulated, one at the C family position and one at the dP4 family position. No second generation waves pass the post-canine positions so that no true replacement teeth are initiated in already existing post-canine families. The possibility that a third *Zahnreihe* exists which involves the incisors and the dC1 is discussed in the text. Degenerative changes in the dental lamina are not illustrated in this figure nor is the true nature of the posteriorly extending terminal free edge of the dental lamina (see Fig. 6).

do not overlap because the waves do not overlap at any one family position. The teeth of adjacent families may come to overlap physically after initiation in such a manner that the tooth of one family comes to overlies the tooth of another family giving the appearance of milk-tooth and permanent successor, but this would and does occur only after the sheet of dental lamina has degenerated. In my opinion this is the relationship between the marsupial P4 and dP4.

Incisor development in *Antechinus flavipes* has not been discussed in the present paper because of difficulties encountered in establishing homologues from one specimen to another due to damage in the incisor areas in sectioning which concealed positional relationships, and the added difficulty of the similar morphology of adjacent teeth. It was clear, however, from the material that all incisor families had two generations. The deciduous teeth generally calcified before they were resorbed. It was not clear how these incisor generations are related to the two postulated cheek-tooth *Zahnreihen* because it has not been possible to determine the relative times of development and calcification of the incisors as compared with the cheek-teeth. It is therefore possible that there are more than two *Zahnreihen* present in the toothrow of *Antechinus flavipes*. The deciduous incisors and deciduous canine may represent one *Zahnreihe*, the permanent incisors, canine and premolars the second *Zahnreihe*, and the dP4-M4 the third *Zahnreihe*.



Fosse and Risnes (1972a and b) demonstrate that in the peramelids *Isodon obesulus*, *I. macrourus*, and *Perameles gunnii*, the I<sup>5</sup> is ontogenetically less developed in the specimens studied than I<sup>4</sup> or C<sup>1</sup>. This suggests the possibility that a separate *Zahnreihe* exists for the incisors, the posterior member of which is the posterior incisor.

Zeigler (1971) has considered the phenomenon of tooth replacement and *Zahnreihen* in mammals. He also concludes that there are two pulses responsible for the production of teeth in mammals but visualizes a greater area of overlap of the two waves than there is evidence for in the present study.

Recently the concept of *Zahnreihen* as visualized by Edmund (1960) has been criticised. Osborn (1970, 1971 and 1972) and DeMar (1971, 1973) have presented alternative hypotheses to explain tooth eruption sequences. Osborn (1970) reviews tooth development in some eutherians and concludes that it does not support Edmund's (1960) contention of two overlapping *Zahnreihen* in mammals. Instead he visualizes between three and six replacement waves. Difficulties which arise from Osborn's interpretation include the need to allocate homologous teeth (e.g. the permanent canines) of different genera to different *Zahnreihen*. Osborn believes this may not be a problem providing the *Zahnreihen* are not visualized as immutable. Osborn (1971) presents evidence for believing that, in *Lacerta*, *Zahnreihen* as visualized by Edmund (1966) are not involved in tooth production. DeMar (1971, 1973), working from data including Osborn's (1970) summary, proposes new geometric ways of interpreting tooth eruption. Neither Osborn nor DeMar, however, make reference to marsupial tooth eruption sequences. This is unfortunate, as it is perhaps only in the marsupials that mammalian tooth eruption sequences of the sort proposed by Edmund appear to take place. The data presented in the present study indicate that, contrary to Osborn's (1970) opinion, the teeth do in fact develop and erupt in sequence from anterior to posterior along the dental lamina in the order which is required by passing waves of the *Zahnreihe* theory.

Osborn (1972) has since developed his earlier (1971) idea and suggests that tooth initiation may be a function of released inhibition. Although the observations reported here are described as *Zahnreihen*, they could equally well be interpreted as the result of released inhibition. More work with other polyprotodont marsupials will be required before the process of tooth initiation in marsupials is understood. In particular, close attention should be given to longitudinal growth of the dental lamina between established tooth positions.

The possibility must remain that tooth eruption sequences in eutherians and marsupials are fundamentally different because there would seem to be no diphyodonty in the cheek-teeth of marsupials and the two *Zahnreihen* have no overlap. It has long been held that the two groups have markedly different patterns of

diphyodonty (in that only the last premolar was replaced) as well as differences in cheek-tooth numbers.

#### *Premolar number and terminology*

Although it does seem probably that eutherians and metatherians originally had the same number of premolar positions, there does not seem to be enough information available to determine which premolar position has been suppressed in the metatherians. Archer (in preparation) demonstrates that supernumary premolars are known to occur in dasyurids anterior to the P1, between the P1 and P3, and even posterior to the P4. Accordingly, arguments for particular premolar family loss based solely on teratology are unsound.

#### *The concept of missing P2*

Ride (1964) and Mahoney & Ride (1974) have summarized some aspects of premolar homology in marsupials. The premolar terminology used by Ride is that used by Thomas (1887). Thomas argues that the occasional appearance of an extra premolar between P1 and P3 is an atavistic reappearance of a suppressed tooth homologous with the eutherian P2. Accordingly he proposes that the normal marsupial premolars be called P1, P3, and P4. However, no one has demonstrated clear embryological evidence for a suppressed tooth family in the P2 position. Woodward (1896, p. 184) claims to have found it as "... an enormous gap between pm1 and pm2 both above and below, this is bridged over by dental lamina, which shows a slight indication of being swollen, this probably represents Thomas' missing pm2, the adult premolars being the 1st, 3rd and 4th." He notes this in *Antechinus* and a similar development (p. 286) in *Dasyurus*. There was however no evidence for a P2 family position in the *Antechinus flavipes* examined in the present study.

#### *The concept of a missing P1*

Ziegler (1971) has recently re-examined concepts of premolar loss in mammals and has concluded that all the marsupials and most eutherians have lost a premolar from the anterior end of the premolar row. In this he has reached the same conclusion as Owen (1840-45), but I know of no embryological evidence for this loss in marsupials. Ziegler has pointed out that in mammals premolar loss generally proceeds by loss first of the replacement tooth followed by loss of the deciduous tooth in a tooth family. This loss proceeds from anterior to posterior along the premolar row. I can find no palaeontological or ontological evidence for these trends in marsupials.

#### *The concept that the premolariform series is complete but that P4 may occasionally be lost*

The evidence that is available suggests that C-P4 is a complete unit representing a *Zahnreihe* but that in dasyurids there is a general trend towards reduction of the posterior premolar family, with loss of this tooth in several



dasyurid genera (*Dasyurus*, *Dasyercus*, *Dasyuroides*, some *Antechinus*, some *Planigale*, and some *Myoictis*).

This study shows that there are no true premolars in *Antechinus flavipes* if premolars are defined in the terms of Owen (1840-45) as those post-canine teeth which possess milk predecessors. This definition is the basis of the modern dental terminology applied to the cheek-teeth of mammals. However, it is clear that there are two different morphological kinds of cheek-teeth in *Antechinus flavipes* and that the teeth of each of the two kinds (i.e. premolariform and molariform) have a unity in origin best expressed by the concept of *Zahnreihen*. If studies of other metatherians demonstrate a similar situation, it may be desirable to redefine the kinds of cheek-teeth and to develop a nomenclature that reflects the *Zahnreihen*.

**Acknowledgements.**—I am most grateful to Dr W. D. L. Ride, Director of the Western Australian Museum, for his helpful criticism and advice. Mr G. Burns of the University of Western Australia helped extensively with the sectioning of the material studied. Dr T. K. Kirkpatrick of the Queensland Department of Primary Industries kindly allowed me to examine his doctoral thesis on the development of kangaroo teeth. My wife Elizabeth helped extensively in raising the animals involved in this study. During the course of this research, the author held a Fulbright Scholarship, a grant in aid from the American Explorer's Club and was a Research Assistant to Dr W. D. L. Ride who was in receipt of a Research Grant from the Australian Research Grants Committee. This work is part of a broader investigation into the phylogeny of the Dasyuridae carried out as doctoral research supervised by Dr W. D. L. Ride.

## References

- Berkovitz, B. K. B. (1966).—The homology of the premolar teeth in *Setonix brachyurus* (Macropodidae: Marsupialia). *Archs oral Biol.* 11: 1371-1384.
- (1967).—The dentition of a 25-day pouch-young specimen of *Didelphys virginiana* (Didelphidae: Marsupialia). *Archs oral Biol.* 12: 1211-1212.
- (1968).—Some stages in the early development of the post-incisor dentition of *Trichosurus vulpecula* (Phalangerioidea: Marsupialia). *J. zool. Res.* 154: 403-414.
- (1972).—Ontogeny of tooth replacement in the Guinea Pig (*Cavia cavia*). *Archs oral Biol.* 17: 711-718.
- Churchill, H. R. (1935).—*Meyer's normal histology and histogenesis of the human teeth and associated parts*. Lippincott Co., Philadelphia, I-VIII + 1-305.
- Clemens, W. A., Jr. (1966).—Fossil mammals of the type Lance Formation, Wyoming. Part II. Marsupialia. *Univ. Calif. Publ. geol. Sci.* 62: 1-122.
- Dawson, A. M. (1926).—A note on the staining of the skeleton of cleared specimens with alizarin red S. *Stain Tech.* 1: 123-124.
- DeMar, R. (1972).—Evolutionary implications of *Zahnreihen*. *Evolution* 26: 435-450.
- (1973).—The functional implications of the geometrical organization of dentitions. *J. Paleont.* 47: 452-461.
- Dressel, H. (1931).—Über die Zahnentwicklung bei *Didelphys*. *Gegenbaurs morph. Jb.* 68: 434-456.
- Edmund, A. C. (1960).—Tooth replacement phenomena in the lower vertebrates. *Contr. Life Sci. Div. R. Ont. Mus.* 56: 1-190.
- Englehardt, H. (1933).—Über die Zahnentwicklung bei *Aepyprymnus rufescens*. *Gegenbaurs. morph. Jb.* 71: 77-94.
- Fosse, G. (1969).—Development of the teeth in a pouch-young specimen of *Antechinus stuartii* and a pouch-young specimen of *Sminthopsis crassicaudata*. Dasyuridae: Marsupialia. *Archs oral Biol.* 14: 207-218.
- and Risnes, S. (1972a).—Development of the teeth in a pouch-young specimen of *Isodon obesulus* and one of *Perameles gunnii* (Peramelidae: Marsupialia). *Archs oral Biol.* 17: 829-838.
- (1972b).—Development of the incisors in two pouch-young stages of *Isodon macrourus*. *Archs oral Biol.* 17: 83-845.
- Kirkpatrick, T. H. (1969).—*The dentition of the marsupial family Macropodidae with particular reference to tooth development in the grey kangaroo Macropus giganteus Shaw*. Unpublished thesis, University of Queensland: 1-128.
- Littich, F. (1933).—Über die Zahnentwicklung bei einem 6 cm langen Didelphysjungen. *Gegenbaurs morph. Jb.* 72: 303-308.
- Mahoney, J. and Ride W.D.L. —(in press).
- Osborn, J. W. (1970).—New approach to *Zahnreihen*. *Nature, Lond.* 225: 343-346.
- (1971).—The ontogeny of tooth succession in *Lacerta vivipara* Jacquin (1787). *Proc. R. Soc., Lond.* 179: 261-289.
- (1972).—On the biological improbability of *Zahnreihen* as embryological units. *Evolution* 26: 601-607.
- Owen, R. (1840-5).—“*Odontography*”. London, Hippolyte Balliere: LXXIV and 1-665.
- Sinclair, W. J. (1906).—Mammalia of the Santa Cruz Beds. Marsupialia. *Rep. Princeton Exped. Patagonia* 4: 333-460.
- Thomas, O. (1887).—The homologies and succession of the teeth in the Dasyuridae, with an attempt to trace the history of evolution of mammalian teeth in general. *Phil. Trans. R. Soc.* 178: 443-462.
- Wilson, J. T., and Hill, J. P. (1897).—Observations upon the development and succession of the teeth in *Perameles*, together with a contribution to the discussion of the homologies of the teeth in marsupial animals. *Q. J. microsc. Sci.* 39: 427-583.
- Woerdman, M. W. (1921).—Beiträge zur Entwicklungsgeschichte von Zahne und Gebiss der Reptilian. Beiträge IV. Über die Anlage der Ersatzbegins. *Arch. mikrosk. Anat.* 195: 265-395.
- Woodward, M. F. (1893).—Contribution to the study of mammalian dentition. Part 1: On the development of the teeth of the macropodidae. *Proc. zool. Soc. Lond.* 5: 450-473.
- Ziegler, A. C. (1971).—A theory of the evolution of therian dental formulae and replacement patterns. *Q. Rev. Biol.* 46: 226-249.
- (1972).—Processes of mammalian tooth development as illustrated by dental ontogeny in the mole *Scapanus latimanus* (Talpidae: Insectivora). *Archs oral Biol.* 17: 61-76.







## INSTRUCTIONS TO AUTHORS

Contributions to this Journal should be sent to *The Honorary Editor, Royal Society of Western Australia, Western Australian Museum, Perth*. Papers are received only from, or by communication through, Members of the Society. The Council decides whether any contribution will be accepted for publication. All papers accepted must be read either in full or in abstract or be tabled at an ordinary meeting before publication.

Papers should be accompanied by a table of contents, on a separate sheet, showing clearly the status of all headings; this will not necessarily be published. Authors should maintain a proper balance between length and substance, and papers longer than 10,000 words would need to be of exceptional importance to be considered for publication. The Abstract (which will probably be read more than any other part of the paper) should not be an expanded title, but should include the main substance of the paper in a condensed form.

Typescripts should be double-spaced on opaque white foolscap paper; the original and one carbon copy should be sent. All Tables, and captions for Figures, should be on separate sheets. Authors are advised to use recent issues of the Journal as a guide to the general format of their papers, including the preparation of references; journal titles in references may be given in full or may follow any widely used conventional system of abbreviation.

Note that *all* illustrations are Figures, which are numbered in a single sequence. In composite Figures, made up of several photographs or diagrams, each of these should be designated by letter (e.g. Figure 13B). Illustrations should include all necessary lettering, and must be suitable for direct photographic reproduction. To avoid unnecessary handling of the original illustrations, which are usually best prepared between  $1\frac{1}{2}$  and 2 times the required size, authors are advised to supply extra prints already reduced. Additional printing costs, such as those for folding maps or colour blocks, will normally be charged to authors.

It is the responsibility of authors to adhere to the International Rules of Botanical and Zoological Nomenclature. Palaeontological papers must follow the appropriate rules for zoology or botany, and all new stratigraphic names must have been previously approved by the Stratigraphic Nomenclature Committee of the Geological Society of Australia.

Thirty reprints are supplied to authors free of charge, up to a maximum of 60 for any one paper. Further reprints may be ordered at cost, provided that orders are submitted with the returned galley proofs.

Authors are solely responsible for the accuracy of all information in their papers, and for any opinion they express.





Archer, Michael. 1974. "The development of the cheekteeth in *Antechinus flavipes* (Marsupialia, Dasyuridae)." *Journal of the Royal Society of Western Australia* 57, 54–65.

**View This Item Online:** <https://www.biodiversitylibrary.org/item/206149>

**Permalink:** <https://www.biodiversitylibrary.org/partpdf/238218>

**Holding Institution**

Royal Society of Western Australia

**Sponsored by**

Atlas of Living Australia

**Copyright & Reuse**

Copyright Status: In copyright. Digitized with the permission of the rights holder.

License: <http://creativecommons.org/licenses/by-nc-sa/4.0/>

Rights: <https://biodiversitylibrary.org/permissions>

This document was created from content at the **Biodiversity Heritage Library**, the world's largest open access digital library for biodiversity literature and archives. Visit BHL at <https://www.biodiversitylibrary.org>.