

On the Hyobranchial Skeleton and Larynx of the new Aglossal Toad, *Hymenochirus Boettgeri*. By W. G. RIDEWOOD, D.Sc., F.L.S., Lecturer on Biology at St. Mary's Hospital Medical School, London.

[Read 2nd November, 1899.]

(PLATE 31.)

XENOPUS and *Pipa* have for many years been to herpetologists a fruitful source of discussion, by reason of the structural peculiarities which mark them off so sharply from the other Anura, and also on account of the great differences which exist between themselves. They are isolated types which fail to show any marked affinity with any of the Phaneroglossal Anura, and the relatively few features in which they resemble one another some writers would explain away as due to convergence and adaptation to similar conditions of life. The discovery of a third genus of Aglossal Toads marks the beginning of a new era in the history of this little suborder; and it is to *Hymenochirus* that attention will now be turned with the object of ascertaining how far the Anura Aglossa constitute a natural assemblage.

A single specimen of this new form was discovered in 1896 at Ituri, in German East Africa, and was described by Tornier as *Xenopus Boettgeri* (7. p. 163). Several specimens have since been collected from the Benito river, in the French Congo; and the skeletal and other characters detailed by Boulenger in the present year (2) go to show that this writer was fully justified in the claim which he put forward in 1896 (1) that Tornier's new species of *Xenopus* was entitled to generic rank.

Having already made an exhaustive study of the hyobranchial skeleton and larynx of *Xenopus* and *Pipa* (4), I applied to Mr. Boulenger for permission to examine these parts in one of the specimens of *Hymenochirus* belonging to the Natural History Museum. The request was graciously acceded to, and a male and a female specimen were placed at my disposal. For these my thanks are hereby gratefully tendered.

There are certain features in the hyobranchial and laryngeal skeleton of *Xenopus* and *Pipa* which may be regarded as distinctive, occurring in both of these genera and not in any of the Phaneroglossal Anura. The features in question are:—

The presence of a hyoglossal foramen, transmitting the reduced hyoglossal muscle, and originating by a secondary union of the hyoidean cornua.

The presence of a pair of large backwardly directed cartilaginous wings, developed from the branchial skeleton of the larva.

The large size and complexity of the larynx, and the incorporation of the thyrohyal bones into the laryngeal apparatus.

The absence of vocal cords.

It is a singular fact that all these five characters are exhibited by *Hymenochirus*.

It does not follow, however, that the hyobranchial skeleton of *Hymenochirus* bears, on the whole, any close resemblance either to that of *Xenopus* or that of *Pipa*. In certain features the hyobranchial skeleton of *Hymenochirus* is unique. The hyoidean cornua, for instance, are very large and strongly ossified. Ossification of the hyoidean cornua, though not uncommon in the Urodela, has hitherto been unknown to occur in the Anura. That Boulenger (2), describing a dried skeleton in which the larynx had not been preserved, should have mistaken these bones of *Hymenochirus* for the thyrohyals is thus quite excusable, seeing that in all other forms of Anura the only strongly ossified parts of the hyobranchial skeleton are the thyrohyals.

The hyoid bones (Pl. 31. fig. 1, *ch*) are thinnest at about one-third of their length from the posterior end, and are flattened in the horizontal plane anteriorly. The hinder part slopes outward and upward; and the swollen extremity, which is not tipped with cartilage, is bound by a short, strong ligament to the inferior surface of the large otic capsule. Projecting horizontally from the mesial surface of each bone is a thin lamella of cartilage, with a convex free border, which is evidently the counterpart of the similarly placed lamella of the unossified hyoidean cornua of *Xenopus* (see 4. pl. 8. fig. 1). Anteriorly the flattened hyoid bones terminate in epiphysial plates which are cartilaginous in the female, but exhibit an irregular endochondral ossification in the male.

Lying antero-internally to these latter is a median element, strongly ossified in both sexes, which is unique among adult Anura (fig. 1, *ca*). It is roughly pentagonal in shape, and from its relations to the surrounding parts might be regarded as the equivalent of the basihyal of Fishes. It is most important to

note that it is not homologous with the median cartilage which is lodged between the two hyoidean cornua in the larval *Xenopus* (4. pl. 11. figs. 1 and 2, *bh*); for the latter, by coalescence with surrounding parts, develops into a plate of cartilage which is *behind* the hyoglossal foramen. The median bone of *Hymenochirus* would correspond rather with the anterior of the two cartilages which occupy the median line in the hyobranchial skeleton of the larval *Alytes* (see 6. figs. 1 and 2, *ca*). It is possible that this anterior copula of the Discoglossid larva may later prove to be the true basihyal element; but, for reasons already stated (5. p. 583), it is preferable, for the present, to apply the term basihyal to the posterior copula, or to avoid the use of the word altogether, until further research has satisfactorily demonstrated the homologies of the constituent parts of the hyoid apparatus of the Anura.

The hyoidean skeleton is completed in front by two plates of cartilage, each exhibiting a small area of calcification (*pa*). These plates are doubtless the equivalents of the *processus anteriores* of the common Frog (see 5. fig. 11, *pa*), and represent also the thin lamellæ of cartilage which project from the anterior edges of the hyoidean cornua in *Xenopus* (see 4. pl. 8. fig. 1).

The front part of the hyobranchial skeleton is quite detached from the hinder part, and the relative positions of the two parts to one another and to the mandible and larynx are preserved in fig. 1, Plate 31. The front part undoubtedly belongs to the hyoidean arch exclusively, but it is possible that in the hinder part there is also some cartilage of hyoidean origin. This proposition is based upon the fact that in *Xenopus* and *Pipa* the hyoglossal foramen is formed by the coalescence of the right and left hyoidean cornua in front of the hyoglossal sinus (4). The hyoglossal foramen of *Hymenochirus* (figs. 1 and 3, *h*) is small in size, but its identity is unmistakable, since it transmits a reduced hyoglossal muscle, running from the ventral surface of the larynx to the pharyngeal mucous membrane in front of the glottis. The tract of cartilage which lies anteriorly to this foramen (*ch'*) may, therefore, be considered as a hyoid derivative. It corresponds with the pointed rod of cartilage which in *Pipa* projects in front of the hyoglossal foramen (4. pl. 9. fig. 1, *ch'*).

In the presence of hyoidean cornua *Hymenochirus* differs from *Pipa* and resembles *Xenopus*. In fact, one may say that no portion of the front half of the hyobranchial skeleton of *Hymeno-*

chirus is represented in the adult *Pipa*. The other half, however, will bear a detailed comparison with the entire hyobranchial skeleton of the adult *Pipa*. The great alary cartilages (*a*), so characteristic of the *Aglossa*, slope outward and backward, and terminate in inwardly directed expansions, which partially overlie the thyrohyals. They extend some distance behind the posterior epiphyses of the thyrohyals in the female, but not in the male (*cf.* figs. 1 and 3). The external geniohyoid muscle is inserted about midway between the hyoglossal foramen and the postero-lateral extremity of the alary cartilage (fig. 1, *ge*), whereas in *Xenopus* it is inserted much nearer the foramen, and in *Pipa* quite close to the postero-lateral border of the cartilage. Lying antero-laterally to the insertion of this muscle is a thin lamellar extension of the cartilage, which finds its exact counterpart in *Xenopus*, but not in *Pipa*. The antero-lateral processes of the basal plate of *Xenopus* (4. pl. 8, fig. 1, *ap*) are not represented, unless they are included in the semicircular tract of cartilage which lies in front of the hyoglossal foramen. The alary portion of the hyobranchial skeleton differs somewhat in shape in the two specimens examined, but the paucity of material precludes one from deciding whether these are normal sexual differences.

In both sexes of *Hymenochirus* the thyrohyal bones have the form of tapering rods, as they have in the female *Xenopus*; and they are brought into intimate relation with the cricoid cartilage of the larynx, as is characteristic of both *Xenopus* and *Pipa*. The posterior ends terminate in large epiphysial cartilages; the anterior ends converge, and are connected with one another by a small tract of cartilage, which in the female is continuous with the transverse bar of cartilage running behind the hyoglossal foramen, but which is bound to the latter by a short stout ligament in the male. These last relations are exactly those obtaining in the two sexes of *Pipa* (see 4. pl. 9, fig. 1, *i*, and fig. 5, *i'*).

The larynx is considerably smaller in the female than in the male, and the thyrohyal bones are shorter, more slender, and set at a wider angle. The floor or ventral wall of the larynx of the female (fig. 3) is largely composed of membrane. It is supported by a horizontal ring of cartilage, from which there project postero-laterally a pair of slender cartilaginous bars. These expand at their extremities into the bronchial cartilages (*br*), and are confluent with the posterior epiphyses of the thyrohyals.

The ring of cartilage is produced into a blunt point in front, while from the sides there rise vertically upwards, internal to the thyrohyal bones, but quite free from them, a pair of cartilaginous bars, which end at the sides of the arytenoid cartilages on the upper surface of the larynx (fig. 4, *bl*). The dorsal extremities of these cartilages appear to be the equivalents of the "Scheuklappenartige Fortsätze" described by Henle (3) in the female *Xenopus*.

As seen from above, the larynx bears a striking resemblance to that of the young *Pipa* (see 4. pl. 11. fig. 11). The dorsal part of the cricoid cartilage has the form of an arched band, running transversely between the posterior epiphyses of the thyrohyals, and fused with them at its extremities. The arytenoids are simple, concavo-convex cartilages, constructed upon the type normal for the Phaneroglossal Anura. They each exhibit a small centre of ossification at the point where the tendinous extremity of the laryngeal dilator is inserted.

There are no vocal cords in either sex, neither are there bronchial tubes. The wall of the lung is quite smooth, and exhibits no sacculation. It is as strongly vascular in the parts connected with the larynx as over the general surface; and it is worthy of notice that the bronchial cartilages of *Hymenochirus* are not more extensively developed than in such a phanerglossal form as *Bombinator* (see 4. pl. 11. fig. 13, *br*). As in *Pipa* and *Xenopus*, the lung is bound to the abdominal wall by a stout pleural fold, which does not quite reach to the posterior extremity.

In the male, the floor or ventral wall of the larynx is composed entirely of cartilage, but the cartilaginous lamellæ projecting from the inner borders of the thyrohyal bones (fig. 1, *t'*) are not confluent with the median cricoid. The latter terminates anteriorly in a sharp point, concealed in a ventral view by the meeting of the thyrohyal lamellæ just mentioned. The vertical bars of the cricoid cartilage, which in the female lie internal to the thyrohyal bones, are also present in the male, and are similarly placed; but they can only be seen by cutting open the larynx. Their dorsal extremities are not free, but are fused with the roofing part of the cricoid cartilage. The cricoid cartilage extends much farther forward on the upper surface of the larynx than it does in the female. It conceals the anterior part of the thyrohyals, and is confluent in front with the tract of cartilage

which has been regarded above as the united anterior epiphyses of the thyrohyals. The actual roof, *i. e.* the part of the cricoid behind the arytenoids, is saddle-shaped, and differs from that of the female in being longer than broad, and in the greater thickness of its cartilage. The arytenoids are completely ossified, no cartilage remaining; and the glottis appears in the prepared skeleton as a rectangular hole. The sides of the glottis are formed by thick folds of mucous membrane occupying the right and left halves of this rectangle. The arytenoids are not confluent with one another as they are in the male *Xenopus*, nor are they backwardly produced into the interior of the larynx as in the male *Pipa*.

The larynx of both sexes is thus of simpler construction than those of the two sexes of *Pipa* and *Xenopus*; but in its hyobranchial skeleton *Hymenochirus* exhibits a most conflicting set of features. It is quite impossible to conclude, from evidence derived from this source, whether *Hymenochirus* is more primitive than the two previously known aglossal toads, or with which of these forms it is the more closely allied. Inconclusive, however, as the results are for this purpose, they constitute a strong argument in support of the view that the Aglossa are a natural group, and that the three genera now composing it have had a common ancestry. The discovery of *Hymenochirus* binds *Pipa* and *Xenopus* more closely together than before.

PAPERS QUOTED.

1. BOULENGER, G. A.—“A new Genus of Aglossal Batrachians.” *Ann. & Mag. Nat. Hist.* [6] xviii. 1896, p. 420.
2. BOULENGER, G. A.—“On *Hymenochirus*, a new Type of Aglossal Batrachians.” *Ann. & Mag. Nat. Hist.* [7] iv. 1899, pp. 122–125.
3. HENLE, D. J.—*Beschreibung des Kehlkopfs.* Leipzig, 1839.
4. RIDWOOD, W. G.—“On the Structure and Development of the Hyobranchial Skeleton and Larynx in *Xenopus* and *Pipa*.” *Linn. Soc. Journ., Zool.* xxvi. 1897, pp. 53–128.
5. RIDWOOD, W. G.—“On the Structure and Development of the Hyobranchial Skeleton of the Parsley-Frog (*Pelodytes punctatus*).” *Proc. Zool. Soc.* 1897, pp. 577–595.
6. RIDWOOD, W. G.—“On the Development of the Hyobranchial Skeleton of the Midwife-Toad (*Alytes obstetricans*).” *Proc. Zool. Soc.* 1898, pp. 4–12.
7. TORNIER, G.—*Kriechthiere Deutsch-Ost-Afrikas.* Berlin, 1897 (1896).

EXPLANATION OF PLATE 31.

- Fig. 1. *Hymenochirus Boettgeri*, male. Hyobranchial, laryngeal, and mandibular skeleton, ventral view. ($\times 6$.)
 2. Laryngeal skeleton of same, dorsal view.
 3. *Hymenochirus Boettgeri*, female. Laryngeal skeleton, and hinder part of hyobranchial skeleton, ventral view. ($\times 6$.)
 4. Laryngeal skeleton of same, dorsal view.
 5. Carpal skeleton of same, dorsal view. ($\times 12$; see page 462.)

Reference Letters.

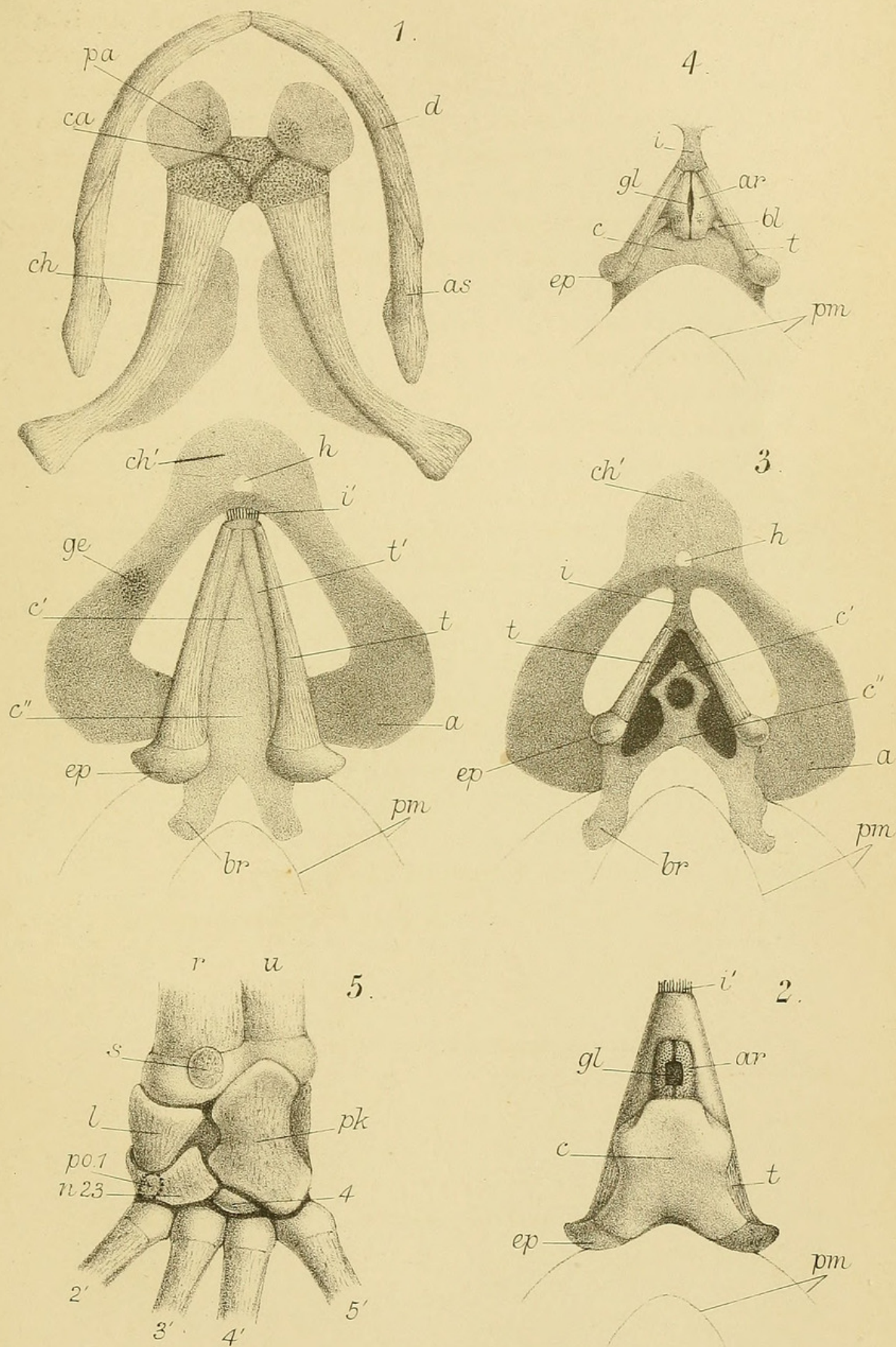
So far as has been possible, the lettering used in Plates 8 and 9, Linn. Soc. Journ., Zool., xxvi. 1897, has been adopted in the present instance.

- a.* Ala, or great wing of the hyobranchial skeleton.
- ar.* Arytenoid.
- as.* Angulosplenic bone.
- bl.* Dorsal extremity of vertical cricoid rod.
- br.* Bronchial cartilage.
- c.* Dorsal or roofing portion of the cricoid cartilage.
- c'.* Antero-ventral portion of cricoid.
- c''.* Postero-ventral portion of cricoid.
- ca.* Ossified copula (*cf.* 6. pl. 2. figs. 1 & 2, *ca*).
- ch.* Ceratohyal or hyoidean cornu.
- ch'.* Median cartilage formed by the secondary union of the hyoidean cornua.
- d.* Dentary bone.
- ep.* Posterior epiphysis of the thyrohyal.
- ge.* Area of insertion of the m. geniohyoideus externus.
- gl.* Position of the glottis.
- h.* Hyoglossal foramen.
- i.* Isthmus between the anterior and posterior portions of the branchial skeleton.
- i'.* Ligament equivalent to the cartilaginous isthmus of the female.
- pa.* Anterior plate of the hyoidean skeleton (*cf.* 5. pl. 35. fig. 11, *pa*).
- pm.* Outline of anterior part of lung.
- t.* Thyrohyal bone.
- t'.* Lamella of cartilage projecting from the thyrohyal bone in the male.

Note on the Carpus of the new Aglossal Toad, *Hymenochirus Boettgeri*. By W. G. RIDEWOOD, D.Sc., F.L.S.

(PLATE 31. fig. 5.)

WHEREAS the carpus of *Xenopus* is comparatively normal, and does not differ in any very essential respect from that of *Disco-glossus* or *Bombinator*, the carpus of *Pipa* is remarkable from





Ridewood, W G. 1900. "On the Hyobranchial Skeleton and Larynx of the new Aglossal Toad, *Hymenochirus Boettgeri*." *The Journal of the Linnean Society of London. Zoology* 27(178), 454–460.

<https://doi.org/10.1111/j.1096-3642.1900.tb00415.x>.

View This Item Online: <https://www.biodiversitylibrary.org/item/98709>

DOI: <https://doi.org/10.1111/j.1096-3642.1900.tb00415.x>

Permalink: <https://www.biodiversitylibrary.org/partpdf/376702>

Holding Institution

Smithsonian Libraries and Archives

Sponsored by

Biodiversity Heritage Library

Copyright & Reuse

Copyright Status: Public domain. The BHL considers that this work is no longer under copyright protection.

This document was created from content at the **Biodiversity Heritage Library**, the world's largest open access digital library for biodiversity literature and archives. Visit BHL at <https://www.biodiversitylibrary.org>.