

PROCEEDINGS OF THE
ENTOMOLOGICAL SOCIETY OF WASHINGTON

VOL. 53

FEBRUARY, 1951

No. 1

UNUSUAL SCALP DERMATITIS IN HUMANS CAUSED BY THE
MITE, *DERMATOPHAGOIDES*

(ACARINA, EPIDERMOPTIDAE)

By JAY R. TRAVER, *Department of Zoology, University of
Massachusetts, Amherst*

The writer and two other members of her immediate family, all of us adult females, have been for the past several years the unwilling hosts to the mite, *Dermatophagoides schermewskyi* Bogdanow. Since the published reports on this mite as a parasite of humans are not numerous, it seems desirable to present an account of the activities of the mite from first-hand information. Symptoms, treatment employed in the attempt to control or eradicate the mite, reaction of certain members of the medical profession to this problem, and the present status of the situation are therefore set forth.

It is to Dr. Edward W. Baker of the Division of Insect Identification, Bureau of Entomology and Plant Quarantine, Washington, D. C., that we owe the identification of this mite, and the synonymy herewith presented. It is to him also that the writer owes her contact with Dr. Gaines W. Eddy of the same Bureau in Washington, who has suggested the use of certain new synthetic organic compounds as scabicides in the treatment of this mite. Had it not been for Dr. Baker's interest in this problem, expressed in personal correspondence, it is quite possible that no attempt would have been made to publish this personal account of an infestation with the mite *Dermatophagoides*.

PERSONAL OBSERVATIONS OF THE ACTIVITY OF THE MITE

Small itching red papules on the scalp were noted as early as 1934. This condition persisted without much change in spite of sporadic efforts to control it, until the spring and early summer of 1943. At this time, the sensations as of some arthropod crawling, scratching and biting became very pronounced, and occurred over wide areas of the scalp. The idea that *Pediculus humanus capitis* might be the causative agent was not borne out since at no time was it possible to 'comb out' a louse nor to locate nits on the hairs. Further, the infestation did not yield to treatment known to be effective against pediculosis. The itching and crawling sensations were most pronounced between about 10 p.m. and the early hours of the morning.

By the middle of August, 1943, the annoyance had become excessive and more strenuous efforts were made to clear up the infestation and to locate the causative agent. Three areas of the scalp were principally involved, a space as large as the palm of the hand above and behind each ear, and an even larger area on the top of the head in the frontal region. The sensations as of something biting, scratching and crawling from place to place were now almost continuous, becoming apparent as early as 10 a.m. and continuing all day and far into the night, increasing in intensity from 11 p.m. onward. Sound sleep was quite impossible. The principal areas involved were also painful and swollen, and as was discovered later, the epidermis over each of them was extremely thickened. On the suggestion of a druggist, a soap containing 1% mercuric iodide was employed as a shampoo. This seemed to irritate the mites, which became very active after the use of this soap. Many of them began to move down out of the scalp, and some of the thickened epidermis began to slough off.

Those that continued down on to the body soon became embedded in itching red papules reminiscent of trombiculid infestations. Treated with strong sulphur ointment they apparently did no further damage. They could be found on the shoulders, under the arms, beneath the breasts, on chest and both upper and lower back, occasionally around the umbilicus. The sensations of crawling and biting which were felt on legs and feet, in the latter case often on but seldom between the toes, indicated that some of the mites had migrated to the lower extremities.

Others of the mites, however, moved down on to the face, invading eyes, ears and nostrils. It was the mites in these locations that did the most damage. Both eyes became so badly swollen that it was impossible to move the eyeballs; to look to right or left it was necessary to move the entire head. Invasion of the eyes was not confined to the period immediately following the use of the mercuric iodide soap, but continued for many days thereafter, this invasion occurring mostly between midnight and 3 a.m. The victim of their attack would have fallen into a light sleep, when a sharp pinprick-like sensation in one eye, followed by an immediate response on the part of the already badly swollen eye would drive sleep away quite effectively. The movements of a mite that had entered under the eyelid could be felt as it crawled slowly about, then began to "dig in" at which moment the eye suddenly became even more swollen than before. An almost continuous flow of lachrymal secretion seemed to attract the mites and made vision difficult. At no time, however, was there evidence of the formation of pus in the affected eyes.

Invasion of the nostrils produced quite distressing symptoms, as of something crawling and scratching in the mucus membrane; often this was accompanied by a distinct irritation of throat, trachea and bronchi. Early invasions of the ears seemed confined to the region of the pinna, in the folds of which the mites burrowed, producing the usual itching red papules. Their presence in the ears was the cause of some concern on my part, as it is well known that certain species of mites may cause great damage in the ears of small mammals. Apparently we may consider ourselves most fortunate that this particular mite did not choose to invade the external auditory meatus, from which location it might easily have pierced the eardrum. The difficulty of controlling such an infestation in the ear, had it occurred, is at once apparent, since as yet we have found no drug that is completely effective against the mites. Even had such a drug been known, its use in the ears might have been inadvisable. Unfortunately for humans, medical doctors are much less versed in dealing with such situations than are the veterinarians who care for our dogs and cats.

In addition to the trouble caused directly by the mites a certain amount of allergic reaction and probably also of secondary bacterial or fungicidal reaction were also present. It is difficult if not impossible to determine how much additional injury and discomfort may have resulted from these secondary infections.

The most acute phase of the infestation yielded to control measures within six weeks. Henceforth, the symptoms previously mentioned became less severe and somewhat chronic, exhibiting an increase in activity more or less periodically every two and one-half to three months. This condition has continued up to the present time. Even this summer (1950), live mites have been taken from all three members of the family. July and August are their periods of greatest activity.

In spite of my optimism in regard to the limited activity of those mites that invaded the ears, there is still a question as to whether or not the difficulty I am now having with my ears, and the rather sudden onset of deafness on the part of the other infested members of my family, may have been aggravated at least by the presence of the mites. Likewise, I wonder if the chronic sinusitis to which I have been heir for some time may also have been increased by those mites which entered the nostrils.

The much-thickened epidermis had sloughed off from the three most heavily infested areas of the scalp before the end of the period of acute symptoms, and since that time no such unusual thickening in these or other parts of the body has

been noted. Itching red papules continue to occur irregularly on the scalp, the pinna of the ears, on the face, and occasionally on neck, chest and back. Such areas frequently become covered with small incrustations. The mites succeeded in establishing themselves temporarily on one wrist, between the third and fourth finger of one hand, just below one ear, on the ventral surface of one knee, and just below the hair line above the left temple. Applications of 2 to 5% aqueous solution of gentian violet to each of these affected areas except the one above the temple, repeated daily for a week or ten days, finally cleared up each of these sites of infestation, some of which were reminiscent of the behavior of *Sarcoptes scabiei*. The network of red lines and itching swellings above the left temple seems also to have been brought under control, largely through the use of sulphur ointment and lysol. There still remain infested areas on the face, in the upper corner of the lower lip and in the right eyebrow, which have not yet been brought under control. Tunnels or burrows, presumably in the dermis, could be seen on the wrist, in the soft skin between the fingers, on the knee, below the ear, above the temple, and on the lower lip. On wrist and knee, these burrows took the form of one more or less straight central tunnel, visible as a slightly raised reddish line, from which extended at right angles several shorter lateral tunnels. Above the temple, as noted, a network of raised red lines with small swellings here and there, indicated the presence of the mites. In other areas mentioned, the tunnels were more or less U-shaped, somewhat wider at one end, and apparently without lateral branches. Inasmuch as it has never been possible to locate a mite in the sloughed-off epidermis or in the small incrustations which form over infested areas, it seems probable that the burrows are actually in the dermis. Further evidence for this belief is the fact that live mites have been captured from the deeper regions underlying such an incrustation when the latter had been removed. Certainly, during the period of acute symptoms, when mites could be felt running about below the thickened epidermal masses, and causing their host almost to tear off bits of the scalp in an effort to get at them, none were even inconvenienced by any substance used against them until the mercuric iodide soap was employed. One of the most annoying runways occupied by the mites, the entire length of the right eyebrow, with extensions to and from the adjacent hair-line, does not show on the surface any indication of its presence save a slight swelling. Even when such a burrow does not show externally, however, its presence is readily ascertainable by reason of the activity of the mites, which habitually travel from one area to another along certain well-de-

finer highways. If these highways were in the epidermis, it should seemingly have been possible to capture mites in them, as the mites moved from place to place.

SYMPTOMS EXPERIENCED BY THE OTHER MEMBERS OF THE FAMILY

It was not until some time after my acute symptoms had subsided that other members of the family began to feel the effects of the mites. Whether they were less susceptible to the mites, from whatever source these were originally obtained, or whether they were infested from my infestation, we shall never know. As I had not at any time discussed the details of my symptoms with either of them, it is evident that they did not develop symptoms 'in sympathy' with mine. Only now and then, one of them would mention her particular symptoms as of the moment. One has had more difficulty with mites invading the pinna of the ear than I have had. These mites, when driven from the ear by the use of sulphur ointment or some other substance, moved down on to the body and became embedded there, particularly on the chest, shoulders and lower back. This member has also had much trouble with mites invading the nostrils. The other member of the family had more difficulty with mites embedded on the neck and shoulders. At no time have either of them suffered acutely from the presence of the mites.

THE MEDICAL PROFESSION

Aid was of course sought from the medical profession, but very little help in treatment of the symptoms was forthcoming from this source. A reliable oculist who was consulted during the period of my acute symptoms reported the finding of some foreign objects embedded in the eye, but as these were apparently not in the cornea, he thought they would do no serious damage. A dermatologist, recommended by a local physician, was apparently convinced without more than a very casual examination, that the patient's symptoms were largely imaginary, those that did exist having been caused by an ill-advised attempt on the part of the patient to rid herself of something that was not there. Not until three days after my visit to his office, however, did he tell me this. Even he could not fail to note the greatly swollen eyes and the three areas of thickened epidermis on the scalp. He X-rayed the eyes and the affected scalp areas, and recommended several days' stay in the hospital, ostensibly for further treatment of the eyes. Actually, such treatment consisted solely of applications of hot boric acid compresses to the eyes, and the use of cold boric acid as an eye wash, treatment which I could have rendered myself at home fully as well. After the

third day in the hospital, he turned me over to a neurologist for treatment of my 'psychoneurotic' condition. The patient, however, succeeded in convincing the neurologist that she had no need of his services. The local physician now suggested the use of sulphur ointment on the scalp, such as had been used effectively by the patient against mites embedded elsewhere on the body. She also suggested the use of sulfathiazole, which seemed to aid materially in reducing the allergic reactions and possible secondary infections. The complete amazement of this physician, when she was later shown some of the first mites to be captured, indicated full well that she, too, had accepted at face value the dermatologist's diagnosis of 'Just imagination.' Hence any real aid in the treatment of the scabitic condition, other than the suggested use of sulphur on the scalp, came from the patient herself or from parasitologists. It is doubtful if the X-raying of eyes and scalp had much effect on the mites, although it may certainly have aided materially in clearing up secondary infections.

TREATMENT

To date, no treatment applied has been able to bring about complete eradication of the mites. However, many substances used on the scalp and elsewhere on the body have afforded welcome even though temporary relief from the annoying sensation produced by the mites. It would seem that a certain number of the substances employed have actually killed some or all of the adult mites, but have had no effect on the ova. Any substance used on the scalp was applied either with sterile cotton or with a pipette, usually being then well rubbed in with the finger tips. Twenty-four to 48 hours was the usual length of time between the application of any one substance and its removal by means of a shampoo, although some substances were left on the scalp for at least a week. The scalp was always shampooed as a preliminary to the application of any substance, and no other substance was used until the preceding one had been thoroughly washed out. After the use of certain of these compounds, a period of two to three months often elapsed before renewed symptoms indicating the presence of the mites were apparent. On circumstantial evidence this might be taken to indicate that the length of time required for the maturation and hatching of a young mite from the ovum is approximately two to three months. There is always the possibility, however, that the young mites may not make their presence felt at once, and that the growth period is really somewhat shorter. Attempts at control have continued actively from 1943 up to the present time.

Many substances employed as a possible means of control proved useless for that purpose. Among these may be mentioned: DDT powder, 10%, used as for pediculosis; kerosene emulsion with vinegar; Sergeant's Mange Cure, which had been of value in treating mange on two pet cats some years before, but was of no help in the present situation; ethyl, normal butyl and isopropyl alcohols, used separately and in varying strengths from 70 to 100%; ether, applied to the scalp a few drops at a time; 3% phenol, also as used for pediculosis

The following chemicals have proved of value in bringing relief, sometimes of a very temporary nature, from the activities of the mite:

Sulphur ointment, 15% USP, applied to the scalp or other parts of the body. This could be left on for several days after application. *It is one of the most helpful substances employed to date.* In the early treatment of mites on the body, a stronger preparation of sulphur was used, made by mixing flowers of sulphur with Crisco or Spry. The exact percent of the sulphur so used was never determined. At one time only during the period of acute symptoms was any sensitivity to sulphur noticed. The ointment used at that time was made up in lanolin. This sensitivity soon disappeared and no indication of it has been felt since that time. Mites treated with sulphur seem to die *in situ*.

Gentian violet, 2 to 5% aqueous solution. This, if left on any affected part of the body for a week or 10 days, and if constantly augmented by additions of the same every few days, proved completely effective in eradicating the small colonies of mites already mentioned, on wrist, knee, fingers and below one ear. Unfortunately it was never feasible to leave this dye on the scalp for more than two days at the most, as it is by no means desirable to go about with one's scalp and hair painted purple. There is also some question as to whether or not gentian violet would prove as effective over areas in which the mites were more deeply located or where they had been 'at home' for a considerable period of time.

Lysol, a relatively strong solution (4 teaspoonfuls to the pint, or even somewhat stronger), *has proved to be one of the most effective methods of killing the adult mites.* It can be used, at this strength, on small areas only. It has the disadvantage of possessing a strong odor and is also hard on the skin. The epidermis usually peels off from any area so treated some time after the use of this solution. In a weaker solution it has been used over the entire scalp following a shampoo, usually being rinsed off in a few hours. It is also by the use

of lysol solution that some of the mites have been captured, as noted below.

Zemo, both regular and extra strength solutions, has proved of value in reducing the irritation caused by the mites' activities, and may even have killed some of the adult mites.

Germicidal soap, 1% mercuric iodide, used as a shampoo, appears to be quite effective against the mites, but does not eliminate all of them, nor does it appear to have any effect upon the ova. This soap is used quite regularly as a shampoo, and since no ill effects have followed its use except at the one period of acute symptoms, it seems evident that this soap cannot have been the causative substance which precipitated the acute attack. No evidence of sensitivity to this soap has been noted. It often causes the mites to migrate, however, which is not desirable if the migration is toward eyes or ears.

Zinc oxide ointment. This has been used at times alone or in combination with sulphur ointment, as is sometimes recommended, to alleviate itching on areas of the face and neck. Painted around each eye, it served to prevent the entrance of many mites into the eyes, as they could be felt moving up to this barrier but going no further.

In addition, certain other compounds known to be of value in the control of sarcoptic and other forms of mange, have been employed. Of these, the first two were suggested by Dr. Gaines W. Eddy, who has recently published the results of a series of experiments with some new synthetic organic compounds as scabicides (*Jour. Investig. Dermatology* 12(2): 117-123, 1949). He likewise sent me samples of several of these substances, enough for two or more treatments with each. It seems quite possible at the present writing that one or both of these two new chemicals may eventually prove effective in the eradication of our mites.

Benzyl salicylate. An aqueous solution of salicylic acid and benzyl ester 10%, in 2% of Tween 20, is the first of these two drugs. Samples of the Tween 20 were kindly donated by the Atlas Powder Company of Wilmington, Del. This has been used on my own scalp for several different doses during the past two months. After each such use, the symptoms were temporarily eliminated, but migration of the mites was quite noticeable. It has recently been employed in the treatment of one of the members of my family, but living mites are still present on her scalp.

2-phenylcyclohexanol 10%, and Tween 20, 2% as an aqueous solution, is the second chemical recommended by Dr. Eddy. The Dow Chemical Company of Midland, Mich., was kind enough to provide me with samples of this compound. It has recently been used on my own scalp. As yet the results

are inconclusive, but again the symptoms are temporarily alleviated. Migration of mites occurs after its use. Ultimate success might be achieved by the frequent repetition of this substance to the scalp and other affected areas, if used repeatedly over a sufficient period of time so as to kill all newly hatched larvae before they reach maturity.

Benzyl benzoate. This has been employed in two forms: first as a liquid, and second as an emulsion, the Wellcome brand, which was much used by British scientists during World War II in the treatment of human scabies. Some relief was obtained from its use, particularly when the emulsion was employed. It seemed especially effective against those mites which had located in the pinna of the ears. Migration of the mites after the use of this compound was most pronounced. Recently, the emulsion has been used on small areas of the scalp at double the strength recommended. Some migration has been caused, but many of the mites seem to have been killed *in situ*. As it is probably unwise to use benzyl benzoate at double strength except on very limited areas, and as it fails to effect a complete cure even when so used, this drug cannot be relied upon to control the mite under consideration.

Tetraethylthiuram monosulphide. Another remedy much used, and with good success according to the literature on the subject, against human and animal scabies. Used as an alcoholic solution as recommended, it has not proved as useful in the treatment of our mite as have several other substances. It is stated to give excellent control against *Sarcoptes* and *Notoedres*, but it seems not to be the answer when used against *Dermatophagoides*.

Gamma isomer of hexachlorocyclohexane. This was used in the form of an ointment sold under the commercial name of KWELL. Ticks and mites are reported to be killed readily by this substance, but not so the mite *Dermatophagoides*. It was left on the scalp for several days before removal with a shampoo, and almost immediately thereafter the mites could be felt moving about in their accustomed places.

40% aqueous hypo (sodium hyposulphite). This was allowed to dry on the scalp, and was followed by a second application, which was also allowed to dry. Sometimes hypo was used alone, or again was followed by 5% HCl after the second application was thoroughly dry. Both methods often brought relief for several days, even for a week or more. But again the ova were evidently not destroyed. Although this treatment has been repeated many times during the past four years, the mites are still with us. However, it did give temporary relief, and caused only a moderate amount of migration on the part of the mites.

Considering the above list of chemicals, many of which are purported to eradicate several species of mites commonly infesting man and domestic animals, it would seem that the mite presently under consideration is much more difficult to deal with than are such genera as *Sarcoptes*, *Notoedres*, *Psoroptes* and *Chorioptes*. Whether or not this is due to an inherent ability of *Dermatophagoides* to withstand strong chemicals or whether, as seems more likely, this mite inhabits the dermis and is therefore less subject to contact with chemicals which are employed against it, we cannot say. At any rate, we have first-hand information that this mite is not easily eradicated.

CAPTURING THE MITE

This was a tedious process, and the number of mites actually captured is surprisingly low. This does not mean, to me at least, that there were not many more mites present at any given time, which could not be captured by any method employed.

My first attempt at locating the causative agent by examining sloughed-off epidermis and incrustations from infested areas, after treating these with KOH, was completely negative. Hence it followed that similar material which was collected from my scalp and body and sent away to two different parasitologists for examination also yielded negative results. Both of the parasitologists were interested in the case, and anxious to help if possible, but they were located many miles away from the individual who had the infestation.

During the period of the acute symptoms, my eyes were so badly swollen that it would have been impossible for me to recognize a mite had I been able to capture it. Furthermore, during that summer I did not have a microscope at my disposal. A few months after the acute symptoms had subsided, however, I captured two very small Hymenoptera which had been felt crawling about on the scalp. These have been identified by Mr. C. F. W. Muesebeck, Chief of the Division of Insect Identification Bureau of Entomology and Plant Quarantine, in Washington, as members of the Trichogrammatidae, known to be egg parasites. There will never be any certainty as to whether or not these Trichogrammatidae bore any relation to the mite infestation, but of course there is always at least a possibility that they were parasitic upon the ova of *Dermatophagoides*. The technic, if one may call it that, of their capture was the same as that which was soon successful in the capture of the first mite found. It consisted in holding a bit of sterilized cotton, dipped in lysol solution, firmly in place for several minutes directly over a spot where a mite or some other arthropod could be felt moving about. Success by

this method was never very great, but at least it was thus that most of the few mites taken directly from the scalp have been captured. If successful, the mite, still alive and moving sluggishly, would be found adhering to the cotton when the latter was removed from the scalp.

A rather amazing number of other arthropods have likewise been captured from the scalp in the same fashion. Among these were: several Hymenoptera of a considerably larger size than the Trichogrammatidae; an oribatid mite; small portions of the skeleton of an unknown arthropod bearing feathered hairs similar to those of a trombiculid mite; what appears to be the cast skin of a small spider; an apparent jassid; and of course many small gnats and other Diptera, among these being psychodids and ceratopogonids. Pollen of various sorts was also found commonly. Perhaps a study of the flora and fauna of the human scalp in summer might be interesting.

A modification of the method of capture indicated above also yielded several mites of *Dermatophagoides*. Immediately following a shampoo, especially when the mercuric iodide soap had been employed for that purpose, mites could be felt moving and scratching at various places on the scalp. Sometimes, following such activity, there would occur a sharp pin-prick-like sensation in a different spot than the original one, and the appearance at that spot of one of the customary itching red papules which often increased in size later. This I interpret to mean that the mite, disturbed but not killed by the substance used in the shampoo, had come up from its "den" in the dermis, and when on the surface of the skin had moved to a new location, when again it burrowed in, perhaps using a hair follicle as its point of entrance. If now the saturated cotton was applied before the second burrowing-in took place, there was a good chance of capturing the mite.

Another method of capture that has met with greater success is as follows. After treatment of the scalp or face with sulphur or indeed with almost any of the chemicals listed as being of value, mites could sometimes be found the following morning on the pillow of the individual using this treatment. These mites, collected by means of a bit of cotton moistened with water, were usually dead when taken, but recently several live, active, impregnated females have been captured in this manner.

At one time only did I succeed in "digging out" a mite from my own scalp, by means of an exploratory fingernail applied to the area beneath an incrustation, the latter having been forcibly removed. The mite had been felt moving about under this incrustation. When thus captured, the mite was

quite alive and healthy, and waved its legs lustily as it was being examined under the microscope.

It is perhaps worthy of note than even a small mite, when moving about actively in or on one's scalp feels "as large as a cat." A peculiar sensation as of pressure sometimes occurs synchronously with the activities of a mite which has been annoyed by treatment with some chemical. This has been especially noticeable after the use of sulphur ointment. Then there is another peculiar sensation sometimes felt: a "streaming" activity, as though many mites, perhaps small ones, were leaving some common center, due to the use on the scalp of some chemical distasteful to them, and "fanning out" in various directions from this center. In fact, some mites may later be located in red papules that had not been there before, on face, neck or shoulders, following such a streaming. I venture to predict that if any dermatologist should become the host of this mite, he would not diagnose *his* case as "Just imagination."

POSSIBLE SOURCE OF THE INFESTATION

The source of the infestation is completely unknown. Two possible sources are: (1) two pet cats of the household, the last one of which died at least ten years ago; these cats suffered from what we called "mange," for which ailment we treated them, with some degree of success, with Sergeant's Mange Cure; and (2) a neighbor's dog, which for years suffered from some severe skin infection which several good veterinarians tried in vain to bring under control, so that the dog had finally to be destroyed. It is possible that our cats acquired their infestation from the dog, and that we acquired ours from either the cats or the dog.

At the time of the most acute symptoms, in the summer of 1943, I tended toward the belief that the infestation had been acquired, in my case, from a woodchuck which I had used to obtain material for some histological preparations. That the woodchuck did have ectoparasites I know for a certainty, as I not only removed from its body some lice (apparently *Enderleinellus marmotae*) but also some immature or nymphal *Ixodes*. I noted some of the latter climbing my arm as I worked on the woodchuck, and later captured one nymphal *Ixodes*, probably *cookei*, from my own scalp. However, the fact that I had noted itching papules in my scalp for some years previous to this time, leads me to believe now that the mite *Dermatophagoides* did not come to me from the woodchuck. This mite has been rather recently reported from rats, but I have had no occasion to work with rats other than to kill an occasional white rat for histological purposes. The same mite has been reported from the skins of birds. But I

have had occasion to come in contact with birds only to pick off a few ectoparasites from such dead specimens as may have been brought into the laboratory, and most of this has been done since 1943.

The fact that the infestation has lasted for so many years seems to indicate that the mite can adjust itself readily to life on or in the human skin, and maintain itself there once it is well established.

TAXONOMIC CONSIDERATIONS

This mite belongs to the family Epidermoptidae, which may be easily distinguished from its nearest ally, the family Psoroptidae, by the fact that the females of the Epidermoptidae possess suckers on all the tarsi, whilst females of the family Psoroptidae have long whiplike setae on the third tarsi.

Dermatophagoides Bogdanow, 1864

Dermatophagoides Bogdanow, 1864. Bull. Soc. Imp. Nat. Moscou 37(1):341-348, pl. 7, figs. 1-2.—Vitzthum, 1929. Tierreich Mitteleuropas, Acari, Bd. 3, 1f. 3, 102.—Sasa, 1950. Japanese Journal of Experimental Medicine 20:519-525.

Pachylichus Canestrini, 1894. Prospetto del' Acarofauna Italiana, fasc. 6:824-829, pl. 77, figs. 1-4.—Berlese, 1897. Acari, Myriopoda, Scorpiones, Cryptostigmata, Sarcoptidae, fasc. LXXXII, no. 12.—Oudemans, 1904, Ent. Bericht. 20:190-195 (synonymy with *Dermatophagoides*).

Mealia Berlese, 1897. Acari, Myriopoda, Scorpiones, Cryptostigmata, Sarcoptidae 1:104.—Berlese, 1898. Idem., fasc. LXXXIX, no. 10, and XCII, no. 3 and no. 4.—Canestrini and Kramer, 1899, Das Tierreich, Demodicidae and Sarcoptidae, 137-138.—Trouessart, 1901, Bull. Soc. Zool. France XXVI:82-84.

Viscopteres Sasa, 1947. Nisshin Igaku 34(3):167-170.

Type: *Dermatophagoides scheremetewskyi* Bogdanow, 1864.

Bogdanow described two forms of mites. The first of these, designated *D. scheremetewskyi*, is a female, depicted in dorsal and ventral view in figs. 1a and 1b. It occurred on the surface of the skin of humans suffering from the itch. The mite of the second type, found on a single occasion on a child suffering from herpes farinosus, and designated by Bogdanow as "*Acarus de l'Herpes farinosus*," is depicted in figs. 2a and 2b. It is a male, very probably that of *D. scheremetewskyi*, as Bogdanow himself suggested; certainly it belongs in the same genus as the previously described female mite. Bogdanow compares his new genus with *Dermatophagus*, saying that it has "une grande ressemblance avec celui des acariens due genre *Dermatophagus*, decrit en detail par Fürstenberg."

He notes two differences between *Dermatophagoides* and *Dermatophagus*: (1) the conformation of two lyre-shaped chitinous arcs near the genital opening of the female; and (2) differences in the termini of the third legs of the females. (*Dermatophagus* Fürstenberg, 1861, is a synonym of *Choriopetes* Gervais, according to Ewing, 1929.)

Dr. Menger, an M.D., reports on the finding of a species of parasitic mite infesting the human skin and causing a severe dermatitis. This mite he describes and figures, as: "*Acarus incapsulator* or *Sarcoptes trichogenetos* (Boeking)." The mite is said to have been found also in capsules beneath the skin of the same patient, and was thought to be related to or be the causative agent of trichinosis, hence the specific name applied to it.

North American records are: Texas; in house in Kentucky; from rat in Florida; from house in Chester, N. H., causing an itch; and from New York. These, combined with the European distribution, indicate a rather widespread range and eventually the mite should be found throughout most of the world.

Several other species have been placed in *Dermatophagoides*, but much work is needed before the exact status of the various species can be determined with certainty. Dr. Manabu Sasa, of the Institute of Infectious Diseases, University of Tokyo, Japan (The Japanese Journal of Experimental Medicine, vol. 20, pp. 519-525, 1950), discusses the genus *Dermatophagoides* in Japan. *D. saitoi* (Sasa) was taken in sputum of a patient with typical Loeffler's syndrome, *D. takeuchii* was found in urine, and an undetermined species was obtained from a patient with chronic bronchial asthma.

Generic characters. Body oval. Dorsal shield present. Prominent transverse groove anterior to middle of body, the two hind pairs of legs posterior to this groove. Sexual dimorphism evident, especially noticeable in legs of male; however, all legs in both sexes are well developed. Posterior end of body more or less rounded, not lobed in either sex. A pair of copulatory suckers present on anal plate of male. Genital opening of female between third coxae; surrounded by a crescentic anterior and two curved lateral sclerotized supports. Corresponding opening of male somewhat more posterior, lying between fourth coxae. Penis short, conical. Epimera of first legs not united. All tarsi in both sexes with short terminal stalks (peduncles) which bear cup-shaped suckers. Claws, where present, small and not easily discernible. Two pairs of long, strong posterior setae, the outer pair longer. One pair of vertical setae, also long and strong, arise from anterior portion of dorsal shield. Chelicerae powerful, terminating in paired chelate cutting surfaces which are dentate on the inner margins. Legs I and II directed forward; legs III and IV directed backward.

***Dermatophagoides scheremetewskyi* Bogdanow**

Dermatophagoides scheremetewskyi Bogdanow, 1864. Bull. Soc. Imp. Nat. Moscou 37(1):341-348.

Mealia pteronyssina Berlese, 1897. Acari, Myriopoda, Scorpiones, Cryptostigmata, Sarcoptidae 1:104.

Acarus incapsulator Menger, 1896. Texas Medical News, San Antonio, Texas, Sept. 25:1-20 (attributed to Boeking).

Sarcoptes trichogenetos Menger, 1896. Texas Medical News, San Antonio, Texas, Sept. 25:1-20 (attributed to Boeking).

Eleven females and nine males, all adults, were available for study. Three of the females, taken alive, were observed before being killed. One larva and two nymphs are also present in the available material. Mites were mounted (a) in clarite, after clearing in xylol, or (b) in modified Berlese's medium, usually direct from 35% alcohol. Some mites were cleared in KOH previous to mounting; others, including most of those mounted by the second method, did not undergo such preliminary treatment. Male mites are almost transparent, but female mites, unless cleared, show well only such structures as are on the surface which is uppermost. Certain morphological features are seen more clearly in mites mounted by the first method; others, by the second.

Size. Female: 10 specimens measured. Average length, 355.2 μ from tips of mouthparts to tip of abdomen; average width, 196.8 μ . Longest, 400 μ ; shortest, 320 μ ; widest, 240 μ ; narrowest, 160 μ . Male: 8 specimens measured. Average length: 296 μ ; av. width, 180 μ . Longest: 352 μ ; shortest, 256 μ ; widest, 208 μ ; narrowest, 128 μ .

Mouthparts. See Plate III, figs. 15, 16, 17, 18 and 19. These are quite complicated, heavily sclerotized, and interpretation of some of the parts is difficult. Two large chelicerae are present, each bearing distally a pair of cutting surfaces, the inner margins of which are dentate or serrate, as indicated in figures 15, 16, 17 and 18. From ventral view, two large triangular or conical structures are seen; from beneath these, the cutting surfaces are visible. Perhaps these represent a bilobed hypostome or rostrum. These structures are shown in the ventral views of male and female mites, Pl. I, figs. 3 and 4. Viewed from above, a very similar pair of triangular structures lying directly beneath the basis capituli almost obscures the cutting surfaces, which can be seen only by focussing downward. These are perhaps the basal portions of the chelicerae, on which the cutting surfaces are borne. It appears, then, that there are two sets of sclerotized, conical structures, one pair dorsal, the other ventral, with the cutting surfaces between them, and attached to the uppermost pair of sclerotized cones. A pair of well-developed palps is present, one palp lying on each side of the conical structures. Each is four-segmented, if the basal segment

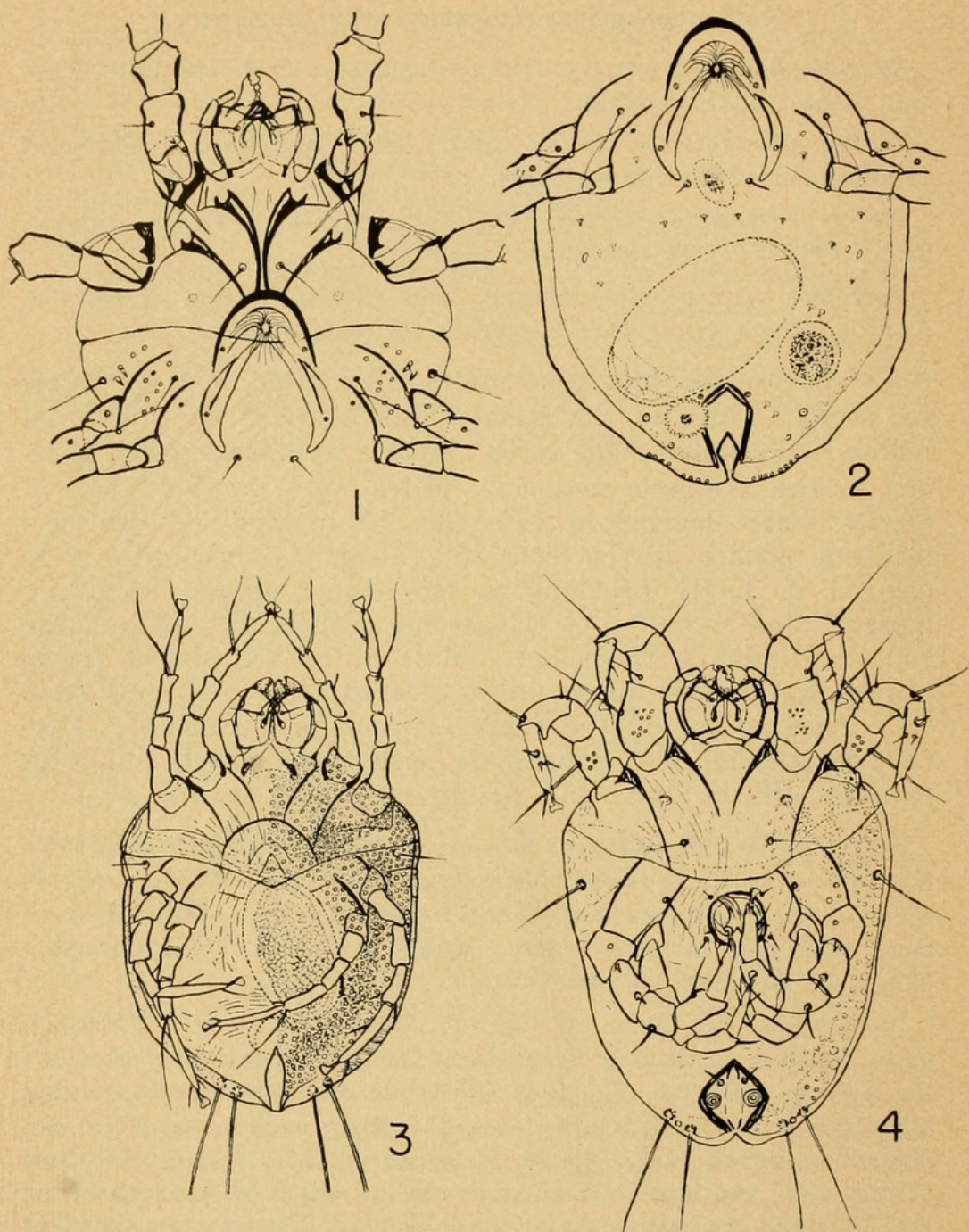


PLATE 1

Fig. 1, adult female mite, ventral view, showing details of skeletal structures; tips of one pair of chelicerae are shown, also location of the pair of large anterior dorsal spines; posterior half of body shown in Fig. 2. Fig. 2, adult female mite, ventral view, showing skeletal structures of posterior half of body. Fig. 3, adult female mite, ventral view; embossings and granulations shown on right side; on left side, fine cuticular lines are indicated; only basal portions of long posterior spines are shown; these are the only dorsal structures seen, except tips of mouthparts. Fig. 4, adult male mite, ventral view; fine granu-

be counted. On each of the paired conical structures are more heavily sclerotized areas; these I am unable to interpret. The pharynx is visible through the mouthparts, especially in specimens well cleared before mounting. The general appearance of the mouthparts is reminiscent of those of *Chorioptes*.

Legs. On all tarsi of both sexes, the short terminal stalks inserted before the end of the tarsus, and bearing prominent cup-shaped suckers, are much like those seen in *Chorioptes*. Stalks on legs III and IV appear slightly longer than those on legs I and II, in both sexes. Tarsi of legs III and IV are likewise longer than those of legs I and II, in both sexes. Setae and spines ornamenting the legs are shown in several of the figures indicated below.

(a) *Female.* See Plate II, figs. 7, 8 and 9; and Plate III, figs. 11 and 13. Legs slender, subequal. In specimens mounted in clarite, a single terminal tarsal claw is seen on leg I. This claw, however, is not clearly evident except under oil immersion. In mites mounted in Berlese's medium, the claw does not show well. On tarsi of legs II, III and IV, one or two lobes are present, but nothing that seems interpretable as a claw.

(b) *Male.* See Plate II, fig. 6; and Plate III, figs. 10, 12 and 14. Legs I and III are definitely much thicker than II and IV; leg I is more thickened than III. Even II and IV, however, are less slender than legs of the female. In males mounted in clarite, claws are discernible, under oil immersion, as follows: Tarsus I, one rather heavy claw and one much smaller; Tarsus II, one claw; Tarsi III and IV, two claws each, one of each pair larger than the other.

Dorsum. Fine cuticular lines are present over the entire dorsal surface, in both sexes. The dorsal shield seems divided into an anterior portion, likewise shield-shaped, and a larger medio-posterior portion; between these, an apparent narrow area which is thinner. On one male, an urn-shaped sclerotized area is present at the anterior margin of the medio-posterior portion, as shown in Plate II, fig. 5. In the male, this dorsal shield seems to extend almost to the posterior tip of the body, and almost to the lateral margins. Large bosses ornament it laterally and posteriorly, as well as a few granulations; the latter are much less conspicuous than in the female. In the female, both portions of the shield are quite heavily granulated, with but a few bosses present. Laterally, a wider area of the body is left exposed than in the male; posteriorly also, the shield fails to cover quite an area. In mounted specimens, the posterior margin appears undulated, but in the live mite it is evenly rounded. In both sexes, but more apparent in the female,

lations and small spines indicated in right half, where also is shown in dotted lines the position of embossings on the dorsal surface; on left half, fine cuticular lines are indicated; location of large, long spines on dorsal shield, in anterior portion, shown in dotted lines; only the basal half of the long posterior spines is shown.

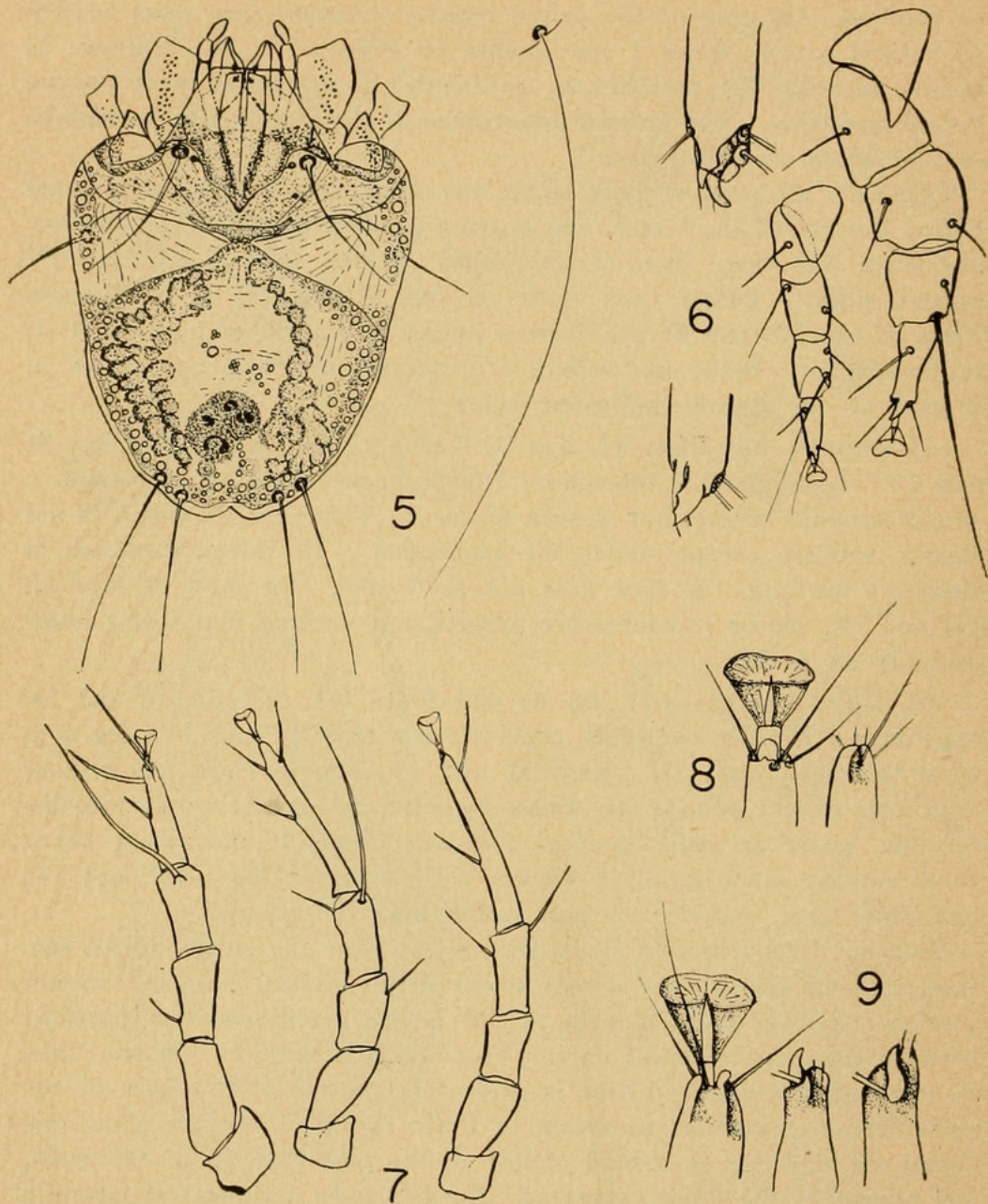


PLATE 2

Fig. 5, adult male mite, dorsal view; structures interpreted as spermathecae and testis are indicated; at right, one of the outer pair of posterior spines, full length. Fig. 6, leg I of male mites; left—tips of tarsi of legs of adult mites, center—leg of young adult, right—leg of fully-developed adult. Fig. 7, legs of adult female mite; left—leg I, center—leg 3, right—leg IV. Fig. 8, tips of tarsi of leg II, adult female mites; right—mounted in clarite, left—mounted in modified Berlese's medium; sucker omitted from leg at right. Fig. 9, tips of tarsi of leg I, adult female mites; center and right—mounted in clarite, left—mounted in modified Berlese's medium; sucker omitted in figures center and right.

a central oval area within the anterior portion seems set off distinctly from the surrounding parts, perhaps due to heavier sclerotization. In the living female, this central portion seems to terminate anteriorly in a sort of triangle overlying the basis capituli. The central area of the medio-posterior portion of the shield in the female is separated from the lateral parts by two deep longitudinal grooves.

Venter. See Plate I figs. 1, 2 and 3, for female mite; and Plate I, fig. 4, for male mite. Definite spines are present on epimera I and II, and on the bars supporting the bases of the legs. Only the coxa of leg I is complete. Fine cuticular lines are present on all parts of this surface also. Openings of the genital apparatus are as noted in generic characters. The anus appears to be subterminal, and is surrounded by a sclerotized border, in which is set one pair of spines. Granulations occur on this surface also, in the female. In all females examined, one large ovum or perhaps a developing embryo occupies a large part of the abdomen. In several females, a round or nearly round structure, with sclerotized margin thicker on one side, lies on or near the mid-line a short distance anterior to the anus. Is it perhaps the ovary? In one male, a granular structure, apparently duplex and interpreted as the testis, occupies approximately the same position; from it extend on each side a series of granules, these being interpreted as sperms within the sperm ducts, since the series of granules terminates near the conical penis.

Body setae. In addition to the granulations, bosses and occasional stubby spines (most numerous on the female), several pairs of setae are present, in both sexes. The most conspicuous of these have been noted in the account of the genus. Four pairs of dorsal and six pairs of ventral setae are recognizable. These include on the dorsum: the strong vertical setae on the anterior dorsal shield; the two pairs of posterior setae, of which the outer pair are longer and stronger than the inner; and a pair of shorter and weaker setae, also on the anterior dorsal shield, and toward the mid-line from the strong pair. Setae of the outer pair of posteriors are usually longer than the body. Ventrally, there is one medium sized pair anteriorly, toward the mid-line; one quite strong pair of laterals arising just anterior to coxa III; three pairs of genitals (in the male, the first two pairs of these are very short, weak and directed inward; in the females, only the bases of the setae can be seen); and one pair of anals, which are relatively better developed in male than in female.

Larva. Only one larva, legs I, II and III present, has been studied. The tips of the legs are curled in such a fashion that it is impossible to be certain of their structure. Body markings in this one specimen resemble those of the male. An oval dark structure laterad of the mid-line might, in that case, be the testis, corresponding to the granular duplex structure seen in the adult male.

Nymph. One male and one female nymph have been found. In each leg IV is now well developed, and in the male the first and third legs

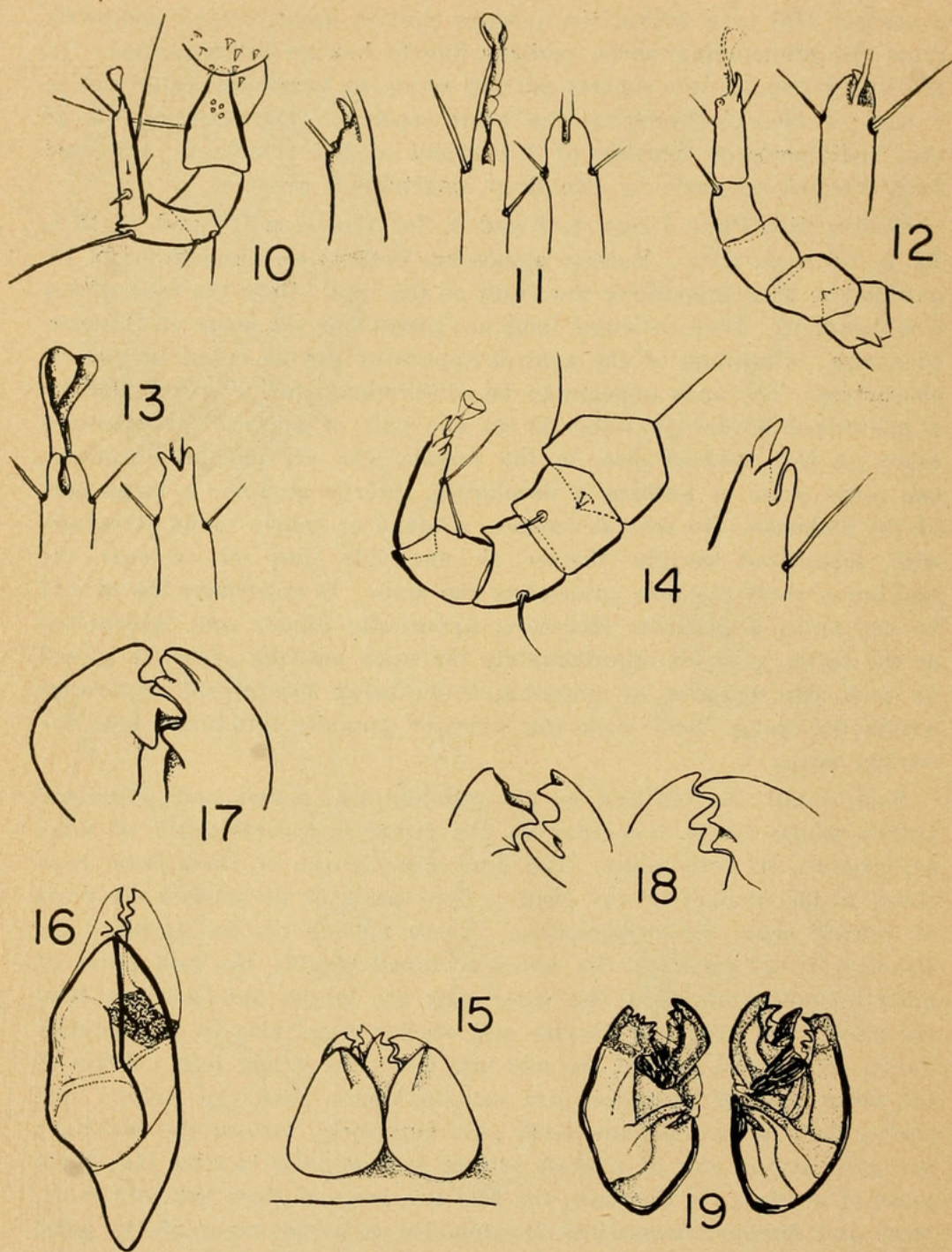


PLATE 3

Fig. 10, leg II of adult male mite; right—tip of tarsus, left—leg. Fig. 11, tips of tarsi of leg III of adult female mites; right—mounted in clarite, left—mounted in modified Berlese's medium; sucker omitted from leg at right. Fig. 12, leg IV of adult male mite; right—tip of tarsus, left—leg. Fig. 13, tips of tarsi of leg IV of adult female mites; right—mounted in clarite, left—mounted in modified Berlese's medium; sucker omitted from leg at right. Fig. 14, leg III of adult male mite; right—tip of tarsus, left—leg. Fig. 15, mouthparts of one male mite

are already thicker than the other pairs. Testis and sperm ducts are evident in this specimen, and the region of the genital aperture is defined, but is apparently not yet functional. In the female, the genital opening and its surrounding sclerotized supporting structures are not yet developed. Nymphs are less heavily chitinized than the adult mites, and tend to become contorted in the process of mounting. In the female specimen, however, the suckers on the tarsi are seen. Legs of the male are so turned that the tips of the tarsi cannot be seen clearly.

OBSERVATIONS ON THE LIVING MITE

Three living females have been observed under the binocular. Each was placed in a Plant Industry watch glass, on a tiny bit of cotton, which was slightly moistened at intervals. The watch glass was covered between periods of observation.

In color, the living female is creamy white as to body, with reddish brown or amber conical mouthparts and paler amber legs. Two or three dark "blobs," apparently close beneath the dorsal surface and in the mid-dorsal line, were observed to change position as the mite moved. Finally one of these was seen to be extruded through the anus. These, then, were food pellets. An opaque colorless rounded structure was seen in one female, anterior to the anus. Perhaps this is the structure postulated to be the ovary.

The mite moved about actively, climbing on and among the fibers of cotton. Often it burrowed into the cotton, using the fore legs to burrow and both pairs of anterior legs to pull the body forward. The third leg seemed used to steer the body. The fourth pair of legs was seldom seen from dorsal view, but probably assists the third pair. Strands of cotton are grasped by the first and second pairs of legs. At one time, when an hour or more had elapsed since the previous observations, the mite could not be seen. It was finally located, hidden completely beneath the entire layer of cotton. Frequently when at rest the mite held the first pair of legs over the mouthparts.

The central oval area of the anterior portion of the dorsal shield appeared amber in color on one mite. It stood out quite distinctly from the areas around it. In another mite, this region was merely less opaque than surrounding portions.

as seen in dorsal aspect, not removed from head of mite. Fig. 16, chelicera, dorsal aspect, after removal from head of female mite; compare with ventral aspect of chelicera from another mite, as shown in Fig. 19. Fig. 17, details of distal cutting edges of chelicera of a female mite. Fig. 18, details of cutting edges of both chelicerae of a male mite. Fig. 19, chelicerae as seen from ventral aspect, after removal from head of female mite; this is a pair taken from the same mite; compare with dorsal aspect of chelicerae from another female mite.

One mite was kept alive for two days, at the end of which period it was as lusty and active as when first caught. Immersion in water, in which the cotton was kept moist, did not seem to disturb the mite. Occasionally a mite would leave the cotton and try to crawl about on the floor of the watch glass, but made little progress.

One mite was killed in warm, not hot, water, in which it died very quickly. A second was immersed in lysol solution of the strength used for treatment of the scalp. For 30 seconds it swam actively, then became quiescent. At 45 seconds, no movement could be detected. It is thus evident that the mites are susceptible and easily killed, if the killing substance can be brought into contact with them. But when in or under the epidermis, they are well protected.

* * * * *

Opportunity is taken here to mention a similar situation in which another mite, *Bdellonyssus sylviarum* (C.&F.), family Laelaptidae (Dermanyssinae), was the causative agent. Several years ago a Mrs. X wrote me in regard to a difficulty which she and other members of her family had been experiencing. They had been suffering considerably from the attacks of an unknown "something" which was present on their scalps and bodies, and which they had been unable to eradicate. Mrs. X, on the advice of her physician, had consulted a dermatologist, who told her she was merely suffering from a "phobia," and to go home and forget it. Two days later, Mrs. X was fortunate enough to capture two dead mites that fell from her scalp. These she took to the dermatologist, who now became interested in her case, and prescribed some lotion as treatment. Meantime he sent the two mites off for identification, and in due time they came to me. I believed them to be *Bdellonyssus sylviarum*, but sent them to Dr. Edward W. Baker for confirmation. He concurred in the above identification.

I have had some further correspondence with Mrs. X on this subject. The last letter, written several months ago, indicated that she was still suffering from the effects of the parasites, and that nothing prescribed by doctor or dermatologist had been of permanent value in controlling her trouble. On the theory that English sparrows nesting under the eaves might have brought the mites into their home, the family had had the entire house fumigated, repainted and repapered, and still Mrs. X suffered from the mites. The other members of her family had meantime recovered from their unpleasant experience with the arthropods.

Here, then, is another instance in which humans, attacked by mites other than *Sarcoptes*, have received scant attention

from the medical profession. Had Mrs. X not been fortunate enough to capture the two mites, she might really have come to believe that she did have a "phobia," whatever that expression may be taken to mean. And even with the causative agent at hand, and identified, the dermatologist was unable to treat the infestation successfully.

A certain parasitologist, in conversation on the subject of mites, has told me that he has had several experiences similar to the above, in which persons fairly frantic from the attacks of some unknown creature had been unable to obtain aid from their doctors, and had written him or come to him for help.

What, on the other hand, could a medical adviser or dermatologist prescribe, in the present state of our lack of knowledge, in such a case? So little is known of the activity and behavior of many mites that may occasionally infest man, and so little also as to the effective methods of treatment. This is, I believe, a subject which is in great need of further investigation. I suggest also that the medical profession might do well to take the lead in such a study.

SUMMARY

The mite *Dermatophagoides scheremetewskyi* Bogdanow, a member of the family Epidermoptidae, is herewith reported as attacking humans, infesting the scalp as well as other parts of the body. Its behavior is *not* similar to that of such mites as *Sarcoptes*. It is believed that the mites burrow down into the dermis, in which they make their runways, and that they occasionally come to the surface from these runways. In general, movements of the mites from place to place are believed to occur within the shelter of these runways.

To date, no treatment employed against the mite has been completely effective, in the sense of killing the ova as well as the adult mites. Nor has repeated re-application of any of the substances used, proved effective in eradication. Many different substances known to be highly effective against *Sarcoptes* and *Notoedres* have been employed as scabicides over the past seven years, in attempts to bring about control or eradication of the mites. Of these, the old standby, sulphur ointment 15%, is the one to which we return again and again, after other substances have failed. Yet it, too, has been unable to eradicate these arthropods. Three compounds which have been most recently used, benzyl salicylate, 2-phenylcyclohexanol, and benzyl benzoate used at double strength, may perhaps be the answer to our problem, but it is still too soon to know. Certain other substances known to be effective against sarcoptic scabies have proved of little value in the treatment of *Dermatophagoides*. Among these are

tetraethylthiurum monosulfide, and benzyl benzoate used at the usual strength.

The infestations here reported have lasted over a period of at least seven years, and have occurred on three adult members of the same family. The source from which the infestation was originally obtained is unknown. If, as we surmise, infested cats or a dog suffering from mange may have been the source or sources, there has been no chance for reinfestation for some years, as these animals have long since died. But there is no certainty that the "mange" from which they suffered was produced by the same causative agent as that which has infested us. It seems probable that the human infestation has lasted for this period of time due to continued self-reinfection of each individual concerned, since the ova are apparently never destroyed by any treatment we have employed. It should be noted that the mites seem to thrive on cleanliness, if weekly, sometimes semi-weekly, shampoos during that entire period of time can be used as a criterion. The mites, be it recalled, occur principally on the scalp.

It is to be hoped that members of the medical profession may soon come to realize that it is possible for humans to be infested with mites other than *Sarcoptes*, give the patient the benefit of the doubt, and try to determine the real cause of the ailment. It is not too easy for a person infested with said mites to make a diagnosis himself, nor to prescribe treatment if he is fortunate enough to locate the causative agent. The medical adviser and the dermatologist, on the other hand, are in a position to add much valuable information in regard to the habits and activities of this and other human-infesting mites, as well as to determine methods of control or eradication, if only they are willing to do so. We can but echo Bogdanow, when he states: "Il serait a desirer que les observations prochains de M. Scheremetewsky et des autres dermatologues nous donnent plus des details sur les acarides, parasites de la surface de la peau de l'homme."

Had it not been that the writer of this article was (1) unwilling to accept the dermatologist's verdict of "Just imagination"; (2) had sufficient knowledge of parasitology and access to enough literature on this subject so that she was able to proceed "on her own" in quest of the invading organisms; and (3) knew how to preserve and mount the mites when found, this mite would in all probability not have been located, and the difficulties experienced would never have been attributed to their real cause. It is quite possible that the mite *Dermatophagoides* infests humans more often than anyone has known, but that its attacks are usually of a minor order, so that the itching and other annoyances caused by its

presence may be attributed by the human host to (1) "imagination," as the doctors would have us believe; (2) "summer heat," since the mites are most active during hot weather; or perhaps (3) "dandruff." A wide-open field exists for anyone enterprising enough to do some real investigation on this subject.

The presence of the mite *Bdellonyssus sylviarum* as a causative agent of dermatitis in the human scalp and on the human body is likewise reported. At last reports, the unfortunate host of this mite was still suffering from its depredations. In this case, the diagnosis had been: "Just a phobia." Here is another field in which to date there has been no competition in the matter of studying the mite as an occasional human parasite.

THE GENUS *PROBEZZIA* IN NORTH AMERICA

(DIPTERA, HELEIDAE)

By WILLIS W. WIRTH, *Bureau of Entomology and Plant Quarantine,
U. S. Department of Agriculture*

The purpose of this paper is to call attention to the proper application of the generic name *Probezzia* Kieffer, to present descriptions of four new species from the United States, to include notes and distribution records for the seven previously known species and to offer a key for their separation.

Most of the material studied is from the U. S. National Museum collection (abbreviated USNM in the distribution lists). Short series were also examined from the California Academy of Sciences (CAS) through the courtesy of E. S. Ross and E. L. Kessel, from Curtis W. Sabrosky's collection of Michigan and Kansas Diptera, and from the writer's personal collection from Louisiana and California.

Genus *Probezzia* Kieffer

Probezzia Kieffer, 1906, Gen. Insectorum, fasc. 42:57; Coquillett, 1910, Proc. U. S. Nat. Mus., 37:594; Malloch (part), 1914, Proc. Biol. Soc. Wash. 27:137; Malloch (part), 1915, Bull. Ill. St. Lab. Nat. Hist. 10:352. (Genotype: *Ceratopogon venustus* Meigen, desig. Coquillett, 1910).

Dicrobezzia Kieffer, 1919, Ann. Mus. Nat. Hungarici 17:127; Ingram & Macfie, 1921, Ann. Trop. Med. and Parasitol. 15:371; Edwards, 1926, Trans. Ent. Soc. London. 74:414; Johannsen, 1943, Ann. Ent. Soc. Amer. 36:785; Lane, 1947, Arq. Fac. Hig. S. Pub. U. São Paulo 1:232. (Genotype: *Ceratopogon venustus* Meigen, orig. desig.). New synonymy.

Diagnosis: Body slender and nearly bare. Eyes bare and usually well separated; antennae with flagellar segments elongate, verticils short and sparse, in male with plumes scanty; palpi slender. Mesonotum without anterior spine or tubercle; dorsum with short scattered erect bristles.



Traver, Jay R. 1951. "Unusual Scalp Dermatitis In Humans Caused By The Mite, Dermatophagoides." *Proceedings of the Entomological Society of Washington* 53, 1-25.

View This Item Online: <https://www.biodiversitylibrary.org/item/54979>

Permalink: <https://www.biodiversitylibrary.org/partpdf/56186>

Holding Institution

Smithsonian Libraries and Archives

Sponsored by

Smithsonian

Copyright & Reuse

Copyright Status: In copyright. Digitized with the permission of the rights holder.

Rights Holder: Entomological Society of Washington

License: <http://creativecommons.org/licenses/by-nc-sa/3.0/>

Rights: <https://biodiversitylibrary.org/permissions>

This document was created from content at the **Biodiversity Heritage Library**, the world's largest open access digital library for biodiversity literature and archives. Visit BHL at <https://www.biodiversitylibrary.org>.